

Optimizing the formation of vesicourethral anastomosis and reduction of procedure time. A two-year experience with a modified technique for endoscopic running vesicourethral anastomosis

Tomasz Golabek¹, Tomasz Wiatr¹, Mikołaj Przydacz¹, Jakub Bukowczan², Przemysław Dudek¹, Robert Sobczynski³, Katarzyna Golabek⁴, Piotr L. Chłosta¹

¹Department of Urology, Collegium Medicum at the Jagiellonian University, Cracow, Poland

²Department of Endocrinology and Diabetes Mellitus, Diabetes Resource Centre, North Tyneside General Hospital, North Shields, United Kingdom

³Department of Cardiovascular Surgery and Transplantology The John Paul II Hospital, Cracow, Poland

⁴Sucha Beskidzka Regional Clinic, Sucha Beskidzka, Poland

Citation: Golabek T, Wiatr T, Przydacz M, et al. Optimizing the formation of vesicourethral anastomosis and reduction of procedure time. A two-year experience with a modified technique for endoscopic running vesicourethral anastomosis. Cent European J Urol. 2015; 68: 296-301.

Article history

Submitted: April 11, 2015

Accepted: May 10, 2015

Published on-line:

Sept. 7, 2015

Corresponding author

Tomasz Golabek
Collegium Medicum at the
Jagiellonian University
Department of Urology
18, Grzegórska Street
31-531 Cracow
phone: +48 12 424 79 50
elementare@op.pl

Introduction Creation of a watertight vesicourethral anastomosis is a challenging and time-consuming procedure. In an attempt to simplify this critical step of radical prostatectomy we have developed a laparoscopic running single suture technique and presented preliminary results previously. Here we report our two-year experience with the Chłosta's single running suture technique.

Material and methods Between January 2013 and June 2014, 60 consecutive patients underwent laparoscopic radical prostatectomy with a running vesicourethral anastomosis using our modified technique for clinically localized prostate cancer. Analyses of the patients' data from a prospectively maintained database with respect to perioperative characteristics, morbidity and urinary continence was performed.

Results The mean anastomotic time was 10.2 min. There was no clinically significant anastomotic leakage observed. Only 3 patients developed perioperative morbidity, but none of them was classified as major. Bladder neck contracture occurred in only one man and it was managed endoscopically. Overall continence rates at 3, 6, 12, and 18 months were 73%, 85%, 96.7%, and 95%, respectively, and 76.8%, 89.3%, 96.4%, and 96.4%, respectively when analysis was limited to those without adjuvant radiotherapy.

Conclusions Obtained results confirm our initial observation from the preliminary report and support the use of our single running suture for the vesicourethral anastomosis in LRP.

Key Words: laparoscopic radical prostatectomy ↔ vesicourethral anastomosis ↔ surgical technique

INTRODUCTION

Laparoscopic radical prostatectomy (LRP) is an established minimally invasive approach for localized prostate cancer [1, 2]. The key step during the procedure is the formation of a watertight vesicourethral anastomosis (VUA). This maneuver, however, remains the most challenging part of the surgery, requiring significant training and experience and

is commonly a time consuming task even in the hands of a capable surgeon [3, 4, 5]. The consequences of an inadequate coupling of the urethral stump to the bladder neck are well known and can significantly affect the patients' quality of life [6]. Moreover, anastomotic urinary leakage and bladder neck contractures may result in urinary retention, a pelvic abscess, and a delayed return of continence, commonly requiring secondary procedures [7, 8, 9].

Laparoscopic vesicourethral anastomosis can be performed with either an interrupted or a running suture with the latter technique gaining more interest recently [10]. We have previously described the preliminary results of our modified method for laparoscopic running vesicourethral anastomosis [11]. Here we report our two-year experience with the technique and the analysis of our data with respect to the perioperative characteristics, morbidity and urinary continence.

MATERIAL AND METHODS

Patient cohort

Between January 2013 and June 2014, 60 consecutive patients underwent laparoscopic radical prostatectomy with a running vesicourethral anastomosis with our modified technique for clinically localized prostate cancer. All procedures were performed by two senior surgeons. Bladder neck preservation technique was applied with a bladder neck circumference approximating the urethral stump before anastomosis, as previously described [12, 13]. Perioperative parameters such as operative time, blood loss, transfusion and conversion rates, drainage output, and catheterization time, were reviewed retrospectively from our prospectively maintained database. Urinary continence status was assessed with the ICIQ-UI Short Form questionnaire at 3, 6, 12 and 18 months after laparoscopic radical prostatectomy. Continence recovery was defined as the use of zero pads. Complications were assessed within a 90-day perioperative period and classified regarding the degree of severity as minor (no hospital admission required), intermediate (required reoperation, conversion, or admission to an intensive care unit for less than 24 hours), and major (life-threatening or requiring hospital stay for more than 24 hours in an intensive care unit and reoperation).

Surgical technique

In our institution, the extraperitoneal approach was the procedure of choice for low risk prostate cancers that did not require lymph node dissection, whereas the transperitoneal technique was applied whenever the extended lymph node dissection was indicated. Immediately after the urethral transection and hemostasis were performed, the vesicourethral anastomosis was fashioned with a continuous running suture with our own modification, as described in detail elsewhere [11]. Briefly, the running stitch (2-0 polyglactin, absorbable synthetic suture) was placed first at the 5-o'clock position on the postero-

lateral aspect of the bladder outside-in and then through the urethra at the same location inside-out (Figures 1 and 2). A gentle traction was applied to the free end of the stitch at the 5 o'clock position throughout the procedure to prevent the anastomosis from loosening or, alternatively, the first stitch could have been tied to keep it secure. Proceeding counterclockwise, the running suture was always driven full thickness and was placed 3 to 5 times

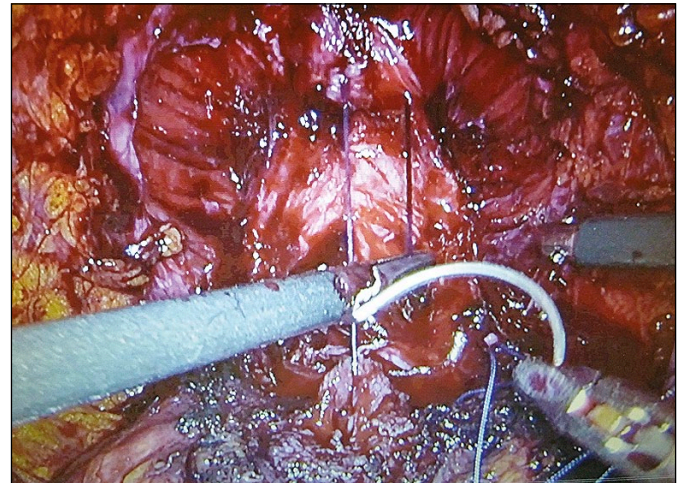


Figure 1. Intraoperative photograph illustrating step one of the Chlosta's technique for performing the single running suture vesicourethral anastomosis. The stitch is placed first at the 5-o'clock position on the posterolateral aspect of the bladder outside-in and then through the urethra at the same location inside-out.

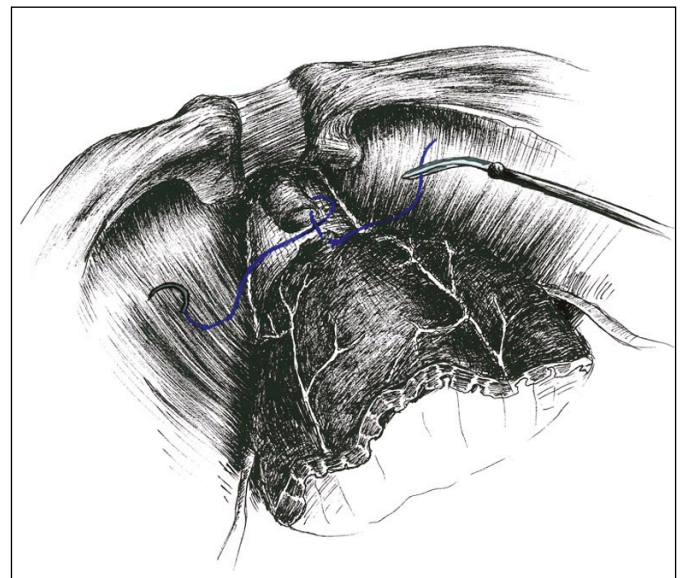


Figure 2. Oblique view illustrating step one of the Chlosta's technique for performing the single running suture vesicourethral anastomosis.

more through both the bladder neck and the urethra in a similar fashion until it met the free-end at the 5-o'clock position (Figure 3). The running sutures were snug down after each apposition to ensure that there was no slack. Just before placing the last

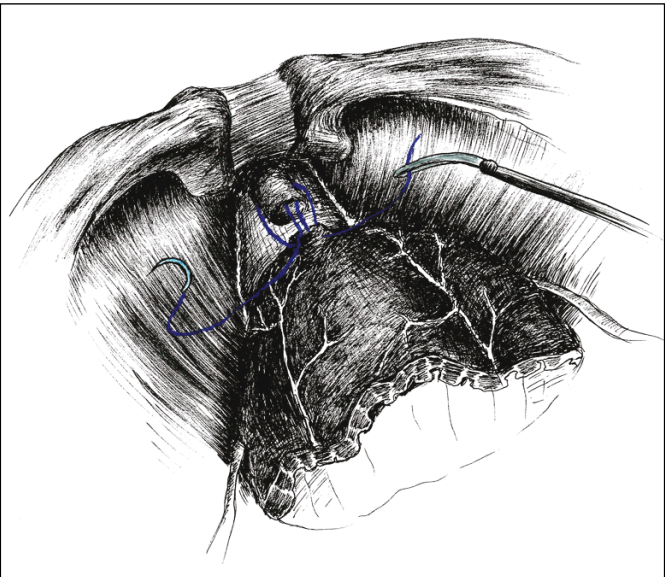


Figure 3. Oblique view illustrating step two of the Chlosta's technique for performing the single running suture vesico-urethral anastomosis. Proceeding counterclockwise, running suture is always driven full-thickness. The suture is placed 4-6 times through both the bladder neck and the urethra until its two ends meet at the 5-o'clock position.

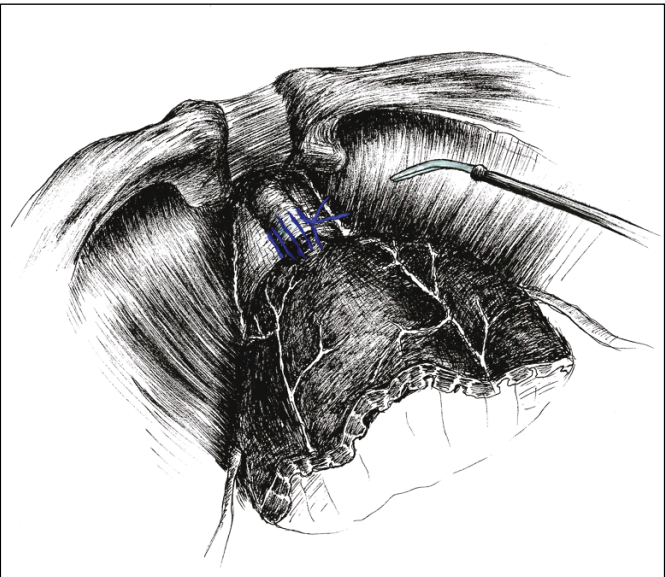


Figure 4. Oblique view illustrating the final step of the Chlosta's technique for performing the single running suture vesico-urethral anastomosis. The both ends of the suture are tied outside the bladder.

stitch, a 18F silicone Foley catheter was inserted into the bladder and its balloon inflated with 10 ml of distilled water. Both ends of the suture were then tied outside the bladder with several knots and a triple knot being the first one, otherwise they were easily undone (Figure 4). To prevent a loose anastomosis a gentle traction was applied on the free-end of the stitch at 5-o'clock position as it entered the bladder throughout the procedure. Upon completion of the anastomosis, the integrity of the urinary reconstruction was tested with filling the bladder with 200 ml of normal saline. A 20F Redon drain was placed in the pelvis by the anastomosis. We did not place traction on the catheter balloon against the anastomosis because it could have resulted in a false negative outcome of the anastomosis integrity test and lack of urinary leakage. The patient was discharged as soon as the abdominal drain was safely removed i.e. its output was less than 100 ml in a 24-hour period and there was no sign of urinary leakage evidenced by a low creatinine concentration in a drain fluid sample. The bladder catheter was removed approximately 2 weeks after the procedure without performing cystography unless there was urinary leakage that persisted.

RESULTS

The patient characteristics and descriptive data are presented in Table 1. The median follow-up was 21 months (range 18-24). The mean age of the patients was 63 years (range 41-76). The mean pre-operative prostate-specific antigen (PSA) level was 10.00 ±8.19 ng/ml. The most common preoperative Gleason score was 6.

Table 1. Patient demographics

| Variable | Value |
|-----------------------------------|---------------|
| Mean Age (±SD), years | 63.00 (±6.54) |
| Mean PSA (±SD), ng/ml | 10.00 (±8.19) |
| Median Preoperative Gleason Score | 6 |
| Preoperative Gleason Score, (n)% | |
| 4 | (1) 1.7 |
| 5 | (3) 5 |
| 6 | (32) 53.4 |
| 7 | (20) 33.4 |
| 8 | (2) 3.3 |
| 9 | (2) 3.3 |
| 10 | 0 |

SD – standard deviation; n – number of cases

The laparoscopic radical prostatectomy was successfully performed in all patients and none of the cases required conversion to open surgery. The mean anastomosis time was 10.20 min (range 5–17). The mean operative time (from skin incision to skin closure) was 148.00 min (range 65–295). The average blood loss was 167 ml, and none of the patients required intra- or perioperative blood transfusions. The mean drainage time was 2.75 days (range 2–4), whereas the average catheterization time was 17.68 days (range 10–21). The mean hospital stay was 6.6 days.

A mild intraoperative anastomotic leak was seen in 2 patients and lasted for 3 and 5 days, respectively; however, no clinically significant anastomotic leakage was observed in any of the cases. There were no intraoperative complications noted and the total 90-day perioperative complication rate was 5% (3 patients). One man developed epididymitis that was successfully treated with a course of antibiotics, while one patient represented to the urol-

ogy department with a short, soft bulbar urethral stricture (patient had a history of previous bulbar urethral stricture treated successfully endoscopically one year prior to LRP), which was successfully managed with an internal optical urethrotomy and finally in one case a bladder neck contracture was present. This was treated with an endoscopic incision 6 months after the laparoscopic radical prostatectomy. Surgical characteristics and perioperative complications are presented in Table 2.

The most common postoperatively determined Gleason sum was 7. The distribution of pathologic stages was 45% pT2, and 55% pT3. After catheter removal the continence rate was 73% at 3 months, 85% at 6 months, 96.7% at 12 months, and 95% at 18 months in the follow-up assessments. However, this study included data from 4 men who had adjuvant radiotherapy within 18 months of surgery. Following exclusion of those cases from the analysis in order to avoid a potential bias associated with an adverse radiotherapeutic effects on the continence mechanism, the resultant data showed greater continence

Table 2. Intra- and perioperative data

| Variable | Value |
|--|-----------------------|
| Surgical characteristics | |
| Mean prostate weight (\pm SD), g | 55.97 (\pm 20.43) |
| Mean anastomosis time (\pm SD), min | 10.20 (\pm 2.81) |
| Mean operative time (\pm SD), min | 148.00 (\pm 40.37) |
| Mean blood loss (\pm SD), ml | 167.03 (\pm 61.19) |
| Transfusion rate, % | 0 |
| Conversion rate, % | 0 |
| Mean drainage time, days | 2.75 (\pm 0.7) |
| Mean catheterisation time (\pm SD), days | 17.68 (\pm 4.20) |
| Mean LOS (\pm SD), days | 6.6 (\pm 0.6) |
| Urinary leak | |
| Intraoperative anastomotic leak (n), % | (2) 3.3 |
| Clinically significant anastomotic leak (n), % | 0 |
| Perioperative complications | |
| Bladder neck contracture (n), % | (1) 1.7 |
| Minor (n), % | (1) 1.7 |
| Intermediate (n), % | (1) 1.7 |
| Major (n), % | 0 |

SD – standard deviation; number of cases; LOS – length of hospital stay; Clinically significant anastomotic leak=leaks that necessitated interventional drainage, or those that resulted in ileus necessitating readmission and intravenous fluids, or those that were associated with fever and signs of sepsis necessitating antibiotic therapy or drainage; 90-day perioperative complications: minor (no hospital admission required), intermediate (required reoperation, conversion, or admission to an intensive care unit for less than 24 hours), and major (life-threatening or required hospital stay of more than 24 hours in an intensive care unit, and reoperation)

Table 3. Oncologic and urinary continence outcomes

| Variable | Value |
|------------------------------------|--------------------------|
| pT2a (n), % | (4) 6.7 |
| pT2b (n), % | (1) 1.7 |
| pT2c (n), % | (22) 36.7 |
| pT3a (n), % | (28) 46.7 |
| pT3b (n), % | (5) 8.2 |
| pT4a (n), % | 0 |
| Median Postoperative Gleason Score | 7 |
| Postoperative Gleason Score, (n),% | |
| 4 | 0 |
| 5 | 0 |
| 6 | (18) 30.0 |
| 7 | (34) 56.6 |
| 8 | (4) 6.7 |
| 9 | (4) 6.7 |
| 10 | 0 |
| Return of continence | |
| | RXT+RXT- |
| 3 months (n), % | (44/60) 73.3(43/56) 76.8 |
| 6 months (n), % | (51/60) 85.0(50/56) 89.3 |
| 12 months (n), % | (58/60) 96.7(54/56) 96.4 |
| 18 months (n), % | (57/60) 95(54/56) 96.4 |

n – number of cases; RXT+ – continence rates of all patients including those who underwent adjuvant radiotherapy; RXT- – continence rates of patients who did not receive adjuvant radiotherapy

rates in all points of evaluation (76.8%, 89.3%, 96.4%, and 96.4%, respectively). Oncologic and continence outcomes are presented in Table 3.

DISCUSSION

The degree of magnification of the operative field that enables more precise identification and dissection of the anatomical structures offered by the laparoscopic system provides the opportunity for a surgeon to perform a vesicourethral anastomosis in a watertight fashion. However, this step still remains a challenging and time-consuming part of the surgery even in the hands of an experienced surgeon. Regardless of the method of VUA being performed, re-establishment of the continuity of the lower urinary tract should be safe, effective and easy to learn by a surgeon, and needs to provide a complete and quick recovery of urinary continence.

In an attempt to simplify the technique and substantially reduce the operative time, we have developed a single running suture laparoscopic vesicourethral anastomosis [11]. This method differs from other techniques as it uses only a single absorbable suture placed four to six times through both the bladder neck and the urethra, with only one knot tied at the end of the procedure, and requires no additional stitches, equipment, or clips such as a Lapara-Ty clip [4, 5, 14, 15].

In our technique we were able to establish a safe approximation of the urethral stump and preserved the bladder neck, which was evidenced by the presence of no clinically significant perioperative anastomotic urinary leak. Postoperative VUA leakage is one of the most bothersome complications of radical prostatectomy. Although it usually heals spontaneously after prolonged catheterization it may result in a poor anastomosis healing, urethral contracture, urinoma, and abscess formation [7, 8, 9, 16]. The reported vesicourethral anastomosis leakage rate after laparoscopic radical prostatectomy was between 0.80 and 17% of cases [7, 17]. With our method, we found that gentle traction applied to the free end of the stitch at the 5 o'clock position throughout the procedure or, alternatively, tying a knot after the first pass of a thread through the bladder wall and the urethral stump, as well as, tying both ends of the suture with several knots upon completion of the procedure, and a triple knot being the first one in order to prevent anastomosis loosening, and consequently ensuring watertightness of the vesicourethral fixation, is of paramount importance.

Additionally, not only does our technique simplify the re-establishment of the continuity of the lower urinary tract, but it also offered a quick reconstruc-

tion of the VUA. The average time of performing an anastomosis was 10.2 minutes, and, even in the hands of an inexperienced resident, it does not exceed 25 minutes. Compared to other series using laparoscopic surgery, the time required to complete anastomosis proved much shorter in our series. Van Velthoven anastomosis that uses two absorbable sutures tied together with two needles at the ends is a relatively complex one with the average reported completion time ranging from 18.2 to 35 minutes [14, 18]. Similarly, a running vesicourethral anastomosis with posterior fixation that is initiated by placing two X-shaped sutures at 5 and 7 o'clock positions as proposed by Branco et al., is a more time consuming technique with the mean VUA time of 37 minutes [19]. Both a running anastomosis performed with V-loc suture, and two knots technique that uses monocryl suture also take considerably more time [4].

Although many urological centers perform a routine postoperative cystography to evaluate the integrity of the VUA before catheter removal [17, 20], we do not find this mandatory unless urinary leakage persists. Upon completion of the surgery, we placed a pelvic drain in the anastomotic site, which was removed when the drainage was less than 100 ml/day. Low creatinine level in the drain fluid was checked routinely just before tube removal confirmed integrity of the VUA.

In the present study, overall urinary continence rates at 3, 6, 12 and 18 months were 73%, 85%, 96.7%, and 95%, respectively. However, this analysis also included data from patients who had adjuvant radiotherapy within 18 months of surgery. To prevent a potential bias, associated with an adverse radiotherapeutic effect on the continence mechanisms, we excluded those men from the analysis. The resultant data showed greater continence rates at all 4 points of assessment (76.8%, 89.3%, 96.4%, and 96.4%, at 3, 6, 12, and 18 months, respectively). It has to be noted that in all cases we preserved the bladder neck using our own technique [12, 13]. This could have improved the continence rates and reduced the number of suture passes through both the bladder neck and the urethra to 4-6 times, consequently shortening the anastomosis time. Our results with respect to continence rates remain comparable with current literature [13, 17, 21, 22].

CONCLUSIONS

We consider our technique for laparoscopic running vesicourethral anastomosis to be the safe and feasible approach for the vesicourethral anastomosis in laparoscopic radical prostatectomy. As this method only

requires the use of a single absorbable suture and placement of one knot at the end of the procedure, it is easy to learn and takes a relatively short operating time. Moreover, this technique ensures good integrity of the anastomosis and appears to carry a low risk of bladder contracture. Results from this study

confirm our initial observation from the preliminary report and support further use of the Chłosta's single running suture vesicourethral anastomosis in LRP.

CONFLICTS OF INTEREST

The authors declare no conflicts of interest.

References

- Gregorio SA, Rivas JG, Molina SS, et al. Laparoscopic radical prostatectomy training for residents: Hospital Universitario La Paz model. *Cent European J Urol*. 2014; 67: 247-252.
- Gözen AS, Akin Y, Özden E, Ates M, Hruza M, Rassweiler J. Impact of body mass index on outcomes of laparoscopic radical prostatectomy with long-term follow-up. *Scand J Urol*. 2015; 49: 70-76.
- Poulakis V, Skriapas K, de Vries R, Dillenburg W, Witzsch U, Becht E. Vesicourethral anastomosis during endoscopic extraperitoneal radical prostatectomy: a prospective comparison between the single-knot running and interrupted technique. *Urology*. 2006; 68: 1284-1289.
- Takeda T, Miyajima A, Kaneko G, Hasegawa M, Kikuchi E, Oya M. Unidirectional barbed suture for vesicourethral anastomosis during laparoscopic radical prostatectomy. *Asian J Endosc Surg*. 2014; 7: 241-245.
- Miki T, Okihara K, Ukimura O, et al. Running suture for vesicourethral anastomosis in minilaparotomy radical retropubic prostatectomy. *Urology*. 2006; 67: 410-412.
- Wang R, Wood DP Jr, Hollenbeck BK, et al. Risk factors and quality of life for post-prostatectomy vesicourethral anastomotic stenoses. *Urology*. 2012; 79: 449-457.
- Chen CC, Yang CK, Hung SW, Wang J, Ou YC. Outcome of vesicourethral anastomosis after robot-assisted laparoscopic radical prostatectomy: A 6-year experience in Taiwan. *J Formos Med Assoc*. 2014; pii: S0929-6646(14)00002-3. doi: 10.1016/j.jfma.2013.12.007
- Polom W, Krajka K, Fudalewski T, Matuszewski M. Treatment of urethrorectal fistulas caused by radical prostatectomy- two surgical techniques. *Cent European J Urol*. 2014; 67: 93-97.
- Ozdemir AT, Altinova S, Koyuncu H, Serefoglu EC, Cimen IH, Balbay DM. The incidence of postoperative ileus in patients who underwent robotic assisted radical prostatectomy. *Cent European J Urol*. 2014; 67: 19-24.
- Albisinni S, Limani K, Hawaux E, Peltier A, Van Velthoven R. Evaluation of the single-knot running vesicourethral anastomosis 10 years after its introduction: results from an international survey. *J Laparoendosc Adv Surg Tech A*. 2014; 24: 640-646.
- Golabek T, Jarecki P, Jaskulski J, Dudek P, Szopiński T, Chłosta P. Modified technique for laparoscopic running vesicourethral anastomosis. *Wideochir Inne Tech Malo Inwazyjne*. 2014; 9: 357-361.
- Chłosta PL, Drewa T, Jaskulski J, Dobruch J, Varkarakis J, Borówka A. Bladder neck preservation during classic laparoscopic radical prostatectomy – point of technique and preliminary results. *Wideochir Inne Tech Malo Inwazyjne*. 2012; 7: 89-95.
- Golabek T, Jaskulski J, Jarecki P, Dudek P, Szopiński T, Chłosta P. Laparoscopic radical prostatectomy with bladder neck preservation: positive surgical margin and urinary continence status. *Wideochir Inne Tech Malo Inwazyjne*. 2014; 9: 362-370.
- Van Velthoven RF, Ahlering TE, Peltier A, Skarecky DW, Clayman RV. Technique for laparoscopic running urethrovesical anastomosis: the single knot method. *Urology*. 2003; 61: 699-702.
- Zarrelli G, Mastropimiano G, Giovannone R, De Berardinis E, Gentile V, Busetto GM. Knotless "three-U-stitches" technique for urethrovesical anastomosis during laparoscopic radical prostatectomy. *Int J Urol*. 2013; 20: 441-444.
- Han KS, Choi HJ, Jung DC, et al. A prospective evaluation of conventional cystography for detection of urine leakage at the vesicourethral anastomosis site after radical prostatectomy based on computed tomography. *Clin Radiol*. 2011; 66: 251-256.
- Tan G, Srivastava A, Grover S, et al. Optimizing vesicourethral anastomosis healing after robot-assisted laparoscopic radical prostatectomy: lessons learned from three techniques in 1900 patients. *J Endourol*. 2010; 24: 1975-1983.
- Simone G, Papalia R, Ferriero M, Guaglianone S, Gallucci M. Laparoscopic "single knot-single running" suture vesico-urethral anastomosis with posterior musculofascial reconstruction. *World J Urol*. 2012; 30: 651-657.
- Branco AW, Kondo W, de Camargo AH, Branco Filho AJ, de George MA, Stunitz LC. Laparoscopic running urethrovesical anastomosis with posterior fixation. *Urology*. 2007; 70: 799-802.
- Nadu A, Salomon L, Hoznek A, et al. Early removal of the catheter after laparoscopic radical prostatectomy. *J Urol*. 2001; 166: 1662-1664.
- Patel VR, Coelho RF, Chauhan S, et al. Continence, potency and oncological outcomes after robotic-assisted radical prostatectomy: early trifecta results of a high-volume surgeon. *BJU Int*. 2010; 106: 696-702.
- Jurczok A, Zacharias M, Wagner S, Hamza A, Fornara P. Prospective non-randomized evaluation of four mediators of the systemic response after extraperitoneal laparoscopic and open retropubic radical prostatectomy. *BJU Int*. 2007; 99: 1461-1466. ■