

Bougie urethral dilators: revival or survival?

Atif Abdulhamid Katib, Mohammad Ahmad Al-Adawi

Department of Urology, King Abdul-Aziz Hospital, Makkah, Saudi Arabia

Article history

Submitted: May 19, 2013

Accepted: Aug. 27, 2013

Correspondence

Atif Katib

Department of Urology

King Abdul-Aziz Hospital

Makkah, Saudi Arabia

phone: +966 2 544 24 00

ext. 2325

atifkatib@gmail.com

Objectives. To present our center's experience in managing bladder outlet obstruction (BOO) conditions using bougie dilators. We described the dilation technique methodically for teaching purpose.

Patients and method. Retrospectively, a total of 196 medical records over the last four years denoting BOO conditions in men, women, and children were retrieved for analysis. Data reviewed for common complications was namely: perforation, recurrence, urinary tract obstruction (UTI) and inability to overcome the obstruction.

Results. Among the 196 analyzed cases, 24 (12.2%) cases were cured, whereas 172 (87.8%) cases reported complications. Within the complicated cases analyzed, 134 (68.4%) cases had recurrent obstructions, 13 (6.6%) cases had perforations, 6 (3.0%) cases developed UTI, while in 19 (9.7%) cases, we failed to pass the obstruction.

Conclusions. In our center where urethral dilation technique has revived four years ago, it turned back to be the standard choice in managing BOO cases. We propose the technique to Urology training program directors, all over the world, to teach it as a compulsory skill for junior urologists to master.

Key Words: urethral dilation technique ◊ bougie dilators ◊ urethral sounds ◊ urethral stricture ◊ BOO

INTRODUCTION

The goal of introducing metal probes into a narrow lumen is to judiciously stretch, calibrate, and unblock narrowings without producing additional scarring. It may be curative in patients with isolated epithelial strictures (no involvement of corpus spongiosum). Etiology of urethral strictures includes fibrosis, inflammation, trauma and congenital malformations. Urethral stricture is a term commonly used for anterior urethral narrowing resulting from inflammatory process, e.g. gonorrheal infection; or traumatic injury, e.g. repeated endoscopies. Scar tissue of the wound contracture strangulates the urethral lumen by reducing its caliber and causing resistance to the normally flowing urine. Depending on the severity of the urethral injury, scarring might extend beyond the mucosa to involve the elastic tissue of the corpus spongiosum in an axial and radial fashion. In contrast to anterior urethral strictures, posterior strictures are far less common. They are due to fibrotic processes that tighten the

bladder neck and result from chronic inflammatory conditions in the bladder, e.g. Schistosomiasis; or post-operative radical prostatectomy or transurethral resection of the prostate (TURP).

The mechanism of dilating a tight tube is by carefully introducing a small-caliber, well-lubricated

Table 1. Common applications of bougie dilators

Dilation of urethral stricture
Dilation of bladder neck fibrosis
Dilation of external urethral meatal stenosis
Dilation of atrophic urethra in postmenopausal women
Dilation of urethral obstruction causing urinary retention
Inserting Foley's catheter mounted on a dilator tip in difficult catheterization and urinary retention settings e.g. post TURP and post bladder-neck suspension (Fig. 4)
Removing ureteric catheters in infants and children [10]
Treating neurogenic bladder [11]

bougie through the cicatrix to increase the lumen diameter by making radial expansion within the tight segment. The process is then repeated with gradually larger sizes of dilators until the narrowing is overcome and the passage is open to normal or nearly normal caliber. Such successful dilation causes rosy red blood droplets resulting from tearing poorly vascularized scar. Excessive expansion of a narrow segment, which is a common pitfall for any excited beginner, can result in blunt trauma to the urethral wall. Consequently, blunt trauma manifests immediately by fresh bleeding and subsequently, by stricture. In the worst scenario the instrument passes throughout the urothelium into the corpus spongiosum or perispongial tissues, resulting in persistent urethral bleeding. This risk can be minimized with a careful technique and an appropriate selection of patients for dilation. In comparison to visual internal urethrotomy (VIU), the global standard choice of treating anterior urethral strictures, we set bougie dilation as the standard way of treating all bladder outlet obstruction (BOO) conditions (Table 2). The procedure of dilating a stenosed urethra, when perfected, allows comparable results to VIU at a given length of stricture. On the other hand, if it was not conducted carefully, sounding would carry the risk of bleeding, perforation, and introduction of infection. Recurrence rate increases with length of the stricture. Recurrence rates at 12 months were 40%, 50%, and 80% for stricture lengths of less than 2 cm, 2–4 cm, and greater than 4 cm, respectively. The recurrence rate for strictures 2–4 cm long increased to 75% at 48 months of follow-up. A prospective randomized comparison of internal urethrotomy and urethral dilation for male urethral strictures found no significant difference in efficacy between the two procedures when used as initial treatment [1].

Internal policy and procedure (IPP) of urethral dilation should include, but not be limited to, the following detailed protocol:

Pre-dilation details

The patient should be evaluated thoroughly, deemed hemostatically stable and have no active urinary tract infection (UTI), urethrocutaneous fistula, nor malignancy in the concerned area. Multiplicity and length of urethral strictures should be clearly depicted in a recent urethrogram. The procedure should be discussed comprehensively with the patient in advance. The discussion should include information regarding the risks and benefits from the procedure, postoperative care, and the clean intermittent catheterization (CIC) program that should follow the dilation procedure. Risks include pain, bleeding,

Table 2. Effects of dilation in the group of 196 patients with BOO

Category of patients	Type of complications	No. of patients
Complicated	Recurrence of obstruction	134 (68.4%)
	Perforation	13 (6.6%)
	UTI	6 (3.0%)
	Inability to overcome the obstruction	19 (9.7%)
Cured	No complications, no recurrence	24 (12.2%)

infection, recurrence of stricture, and perforation. Informed consent must be obtained. No prophylactic antibiotic is required [2]. Two tablets of eight mg lornoxicam (Xefo) is administered orally half an hour beforehand to control pain.

Dilation details

Position the patient in the supine, split-legged or lithotomy position. Scrub and drape the genitalia using an eye-hole towel. Inject plenty of Lidocaine hydrochloride 2% jelly (Xylocaine) intraurethrally for lubrication and local analgesia. Hold it by the penile clamp for 2 minutes. Similarly, apply Lidocaine jelly to the beginning third of the dilator probe. Never start by the smallest probe when dilating a urethral stricture, instead start with a 7 Fr. dilator, as finer probes are more likely to perforate. Fine probes are used to start dilating meatal stenosis under vision. Remove the penile clamp. Using the non-dominant hand covered by a piece of gauze for better control, grab the penis firmly and stretch it while introducing the probe gently with the tip curving up using your dominant hand. Let the probe slide inside by its weight. You might support it by no more than a gentle push using your operating hand's index finger. Ensure that the probe's tip rests on the cicatrix directly. At this critical moment, exercise extreme care on advancing the probe. It should travel in an axial way to the urethral lumen sticking to the dorsal side of the urethra. You should be able to feel the probe sliding down by the palmar surface of your grabbing hand. Inadvertently, if the probe was forced towards the ventral side of the proximal urethra, it might rest in the subtrigonal layer. Once you are in the bladder, the probe's handle should be easily rotated in clock-wise and anti-clock-wise directions, denoting that the curved tip is in the bladder cavity. Keep the probe around 20 seconds and then pull it out firmly, while the penis together with probe's handle are bent cephalad, i.e. towards the patient's abdomen. While removing the probe you should be able to count how many stricture rings you have passed

relying on the number of clicks you feel. Procedure steps are illustrated by figures 1.A,B,D. Repeat the procedure using larger dilators. We declare the procedure “done” when a suitable Foley’s catheter is inserted; or the procedure is “terminated” if a concrete impassable occlusion is encountered.

Post-dilation details

Once the procedure is over, the patient is allowed home on Paracetamol tablets 500 mg q 8 hrs/prn. The urethral catheter is removed in the outpatient clinic after five days and then the CIC program commences. Successfully dilated patients might require further dilations sparingly. If dilation is required less frequently than once every three months with a 20 Fr. sound to attain relief of symptoms and improvement in urinary flow, this mode of treatment should be continued [3]. In case the patient had pro-

fuse urethral bleeding, indicating additional injury, the urethra should rest for three weeks during which an ascending urethrogram should be performed.

METHODS

We faced difficulties in retrieving the proposed files, as dilation notes have no special procedure form, and so we had to check progress notes and doctors’ orders. Cases done under anesthesia were easy to collect as operative notes are readily available. Data from all records (196) under diagnoses pertaining to BOO were analyzed with no stipulations. No exclusion criteria was considered. Common complications in terms of UTI, recurrence, perforation and failure to pass the occlusion were searched (Table 3). Only documented UTIs by urine culture were counted. While one episode of restenosis, documented by a follow up urethrogram, was enough to enroll the patient in the recurrence list.

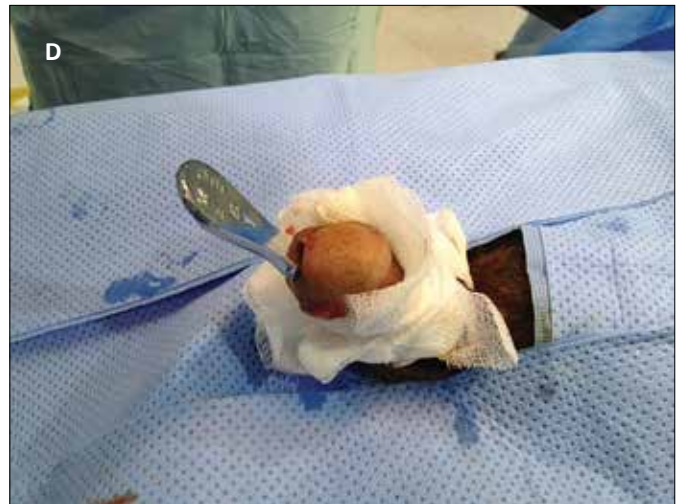
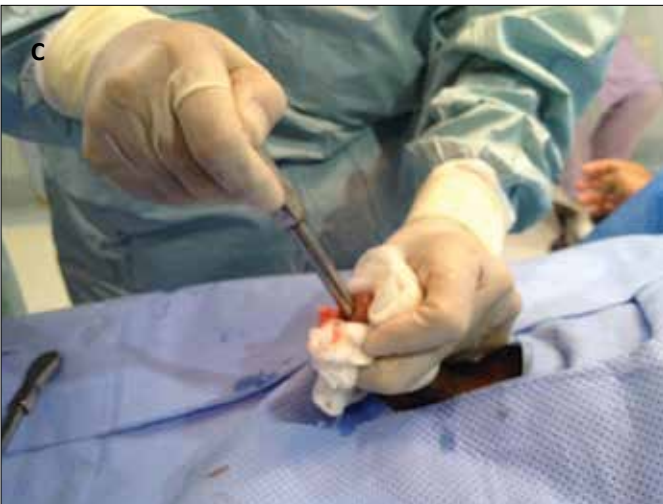
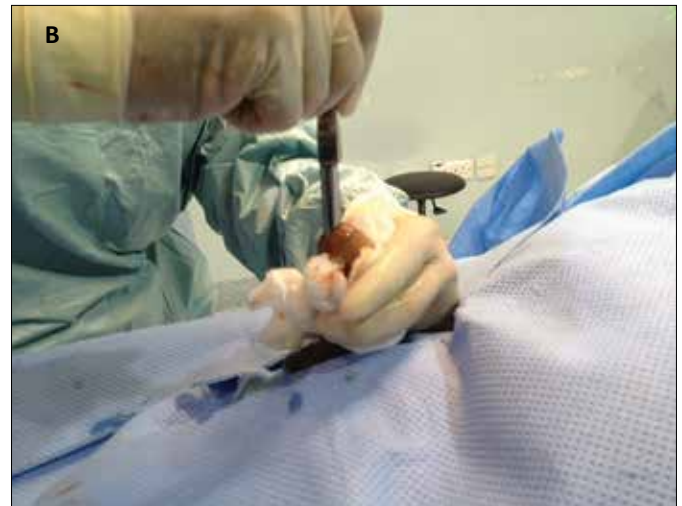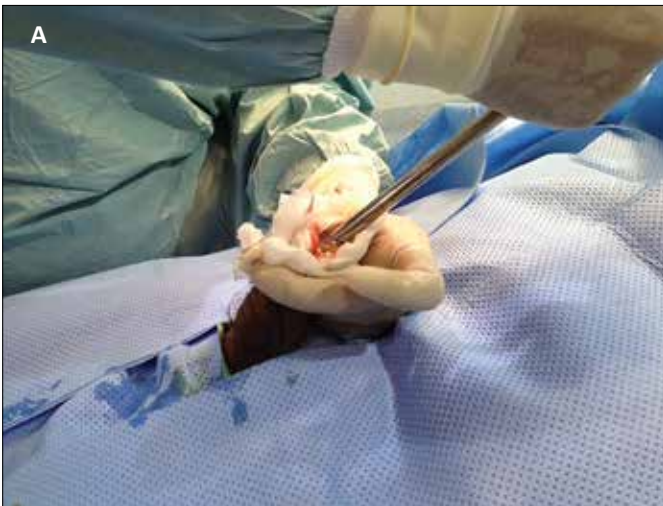Figure 1 A,B,C,D. The following step-wise urethral dilation using bougie probes.

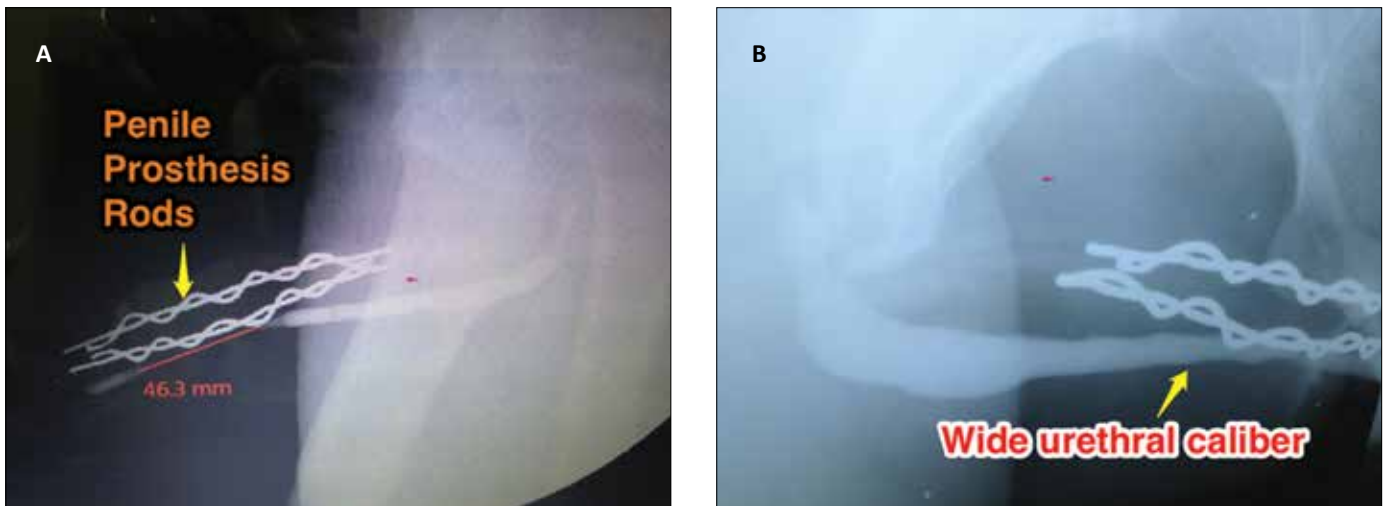


Figure 2A,B. Step-wise dilation technique of urethral stricture using a bougie probe. Urethrograms performed: a) before, and b) after 2 month (of) bougie dilation.

Perforation results from introducing the probe in a false passage, marked by persistent fresh urethral bleeding. Successful dilation means that the obstruction is passed, with the urethral caliber widened to normal or near normal caliber, with no perforation. Such successful dilation ends by the insertion of a suitably sized urinary catheter. Cured cases are those which were dilated successfully and required no further dilations. The follow up in our study was up to six months, covering the CIC program time-frame.

The CIC program starts after removing the urethral catheter as twice weekly for six weeks, followed by once weekly for six weeks, once every two weeks for six weeks, and eventually once a month. The patient

is instructed to come back once he faces difficult catheterization. The workup therefore, includes: uroflowmetry, urethrography and redilation.

RESULTS

Amongst the 196 analyzed cases 24 (12.2%) were cured. The remainder 172 (87.8%) patients developed complications in the form of recurrence of the stricture in 134 (68.4%) cases, perforation in 13 (6.6%) cases, inability to overcome the occlusion in 19 (9.7%) cases, and UTI in 6 (3.0%) cases (Table 3). Pre- and postdilation urethrographies of two selected cases including anterior and posterior urethral strictures are presented on figures 2A,B, 3A, and 3B.

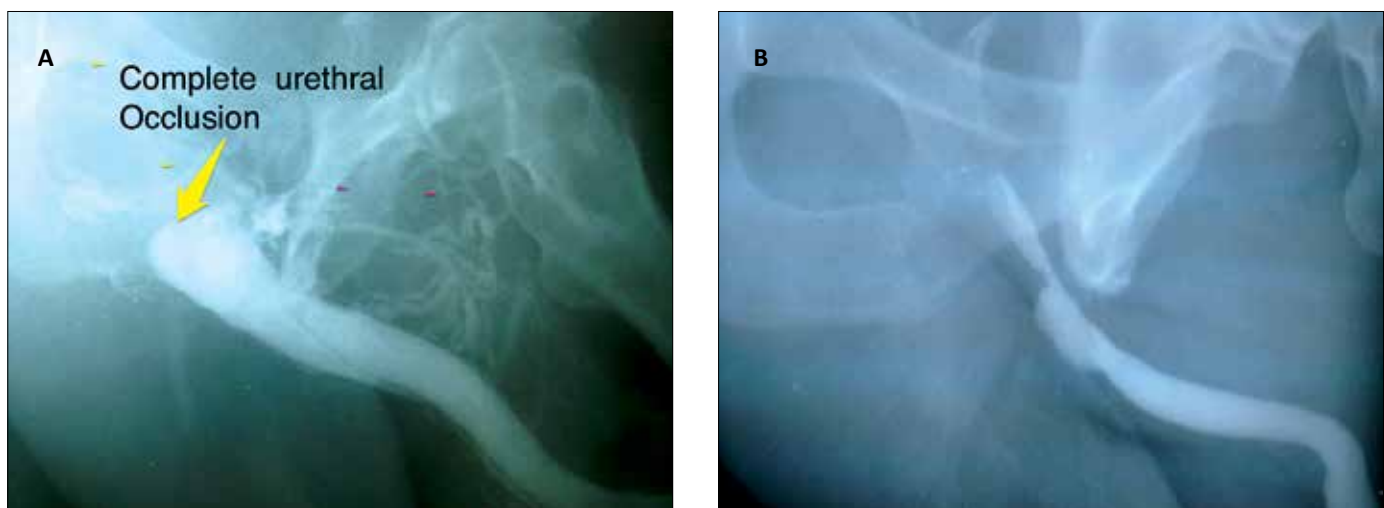


Figure 3A,B. Complete obstruction of posterior urethra. Urethrograms performed: a) before, and b) after 2 month of bougie dilation.

DISCUSSION

With the advent of advanced technology of endoscopy and laser, in many centers bouginage is declared obsolete. We believe that bougie dilation is unquestionably valuable. In our center the technique of bougie dilation has revived after long years of quiescence. It has replaced VIU almost completely. Unless the patient was planned for urethral stent placement, a trial of dilation would be offered routinely. Low pain–threshold patients are dilated under anesthesia. In our practice, urethroplasty is not the first line in treatment of urethral strictures. We instead give all stricture cases a trial of dilation and reserve urethroplasty surgery for impassable cases. Recurrent cases of urethral stricture are redilated. Other researchers proposed an algorithm for the management of recurrent urethral stricture based on cost–effectiveness; and concluded that initial urethrotomy or urethral dilation, followed by urethroplasty in patients with recurrent stricture proved to be the most cost–effective strategy [4]. We use bougies in a wide array of BOO conditions (Table 2). Unsurprisingly, the most frequent complication reported was re-stricture, meanwhile, other complication rates were comparable. Our paper responds to the inquiry raised by Wong et al. [5] surrounding the best treatment modality for urethral stricture disease in terms of efficacy, adverse effects, and costs. There is a multitude of reasons why supporters uphold dilation technique in the 21st century. In hands of the proficient urologist the technique is safe and as effective as VIU. Failed dilation cases are considered ahead for open urethroplasty. Sparing on costs of the operating room, anesthesia, disposables, and hospitalization it is a cost–effective procedure. It can be performed in all types of medical facilities and does not take much time compared to endoscopy and laser techniques. However, critics raise the issue of the procedure being blind. Moreover, video documentation and stent placing are impossible when using dilators. Regardless of the protocol details, the practice of CIC after initial



Figure 4. Foley's catheter mounted on a dilator's (tip).

urethral dilation, whether carried out by the patient himself or other family members, is known to keep the urethra wide for the longest possible time; thus, avoiding re-stricture formation [6, 7, 8].

CONCLUSIONS

Bougie dilators are valuable instruments in hands of a skilled urologist. In centers where the technique of dilation survived or was revived, it is considered the golden standard of treating urethral strictures. Whereas, in centers where the technique fell into oblivion it is worth to make a second look at it and consider restoring this simple but effective procedure to use. Despite the fact that dilation procedure appears deceptively simple, we suggest that it should be included in the Urology residency training program log–books, to increase its practice and convince more urologists to its advantages.

References

1. Steenkamp JW, Heyns CF, de Kock ML. Internal urethrotomy versus dilation as treatment for male urethral strictures: a prospective, randomized comparison. *J Urol.* 1997; 157: 98–101.
2. Fujita K, Matsushima H, Nakano M, Kaneko M, Munakata A. Prophylactic oral antibiotics in urethral instrumentation. *Nihon Hinyokika Gakkai Zasshi.* 1994; 85: 802–805.
3. Luis R. Decision Making in Urology: Urethral Stricture, Adult Male, Saint Louis: The C.V. Mosby Company, 1985.
4. Greenwell TJ, Castle C, Andrich DE, MacDonald JT, Nicol DL, Mundy AR. Repeat urethrotomy and dilation for the treatment of urethral stricture are neither clinically effective nor cost–effective. *J Urol.* 2004; 172: 275–277.
5. Wong SS, Aboumarzouk OM, Narahari R, O'Riordan A, Pickard R. Simple urethral dilation, endoscopic urethrotomy, and urethroplasty for urethral stricture disease in adult men. *Cochrane Database Syst Rev.* 2012; doi: 10.1002/14651858
6. Lauritzen M, Greis G, Sandberg A, Wedren H, Ojdeby G, Henningsohn L. Intermittent self–dilatation after internal urethrotomy for

primary urethral strictures: a case-control study. *Scand J Urol Nephrol.* 2009; 43: 220–225.

7. Kjaergaard B, Walter S, Bartholin J, Andersen JT, Nøhr S, Beck H, et al. Prevention of urethral stricture recurrence using clean intermittent self-catheterization. *Br J Urol.* 1994; 73: 692–695.

8. Bødker A, Ostri P, Rye-Andersen J, Edvardsen L, Struckmann J. Treatment of recurrent urethral stricture by internal urethrotomy and intermittent self-catheterization: a controlled study of a new therapy. *J Urol.* 1992; 148: 308–310. ■