

# Should every patient with hematospermia be investigated? A critical review

Waseem Akhter, Faisal Khan, Frank Chinegwundoh

*Department of Urology, Cheltenham General Hospital, Cheltenham Gloucestershire, United Kingdom*

## Article history

Submitted: May 13, 2012

Accepted: Aug. 24, 2012

## Correspondence

Faisal Rauf Khan  
Cheltenham General  
Hospital  
GL53 7QX Cheltenham  
United Kingdom  
phone: +44 780 959 1041  
drfaisalrauf1979@yahoo.  
com

Hematospermia or hemospermia is defined as the presence of blood in ejaculate. It often invokes considerable anxiety and is frightening for the patient. Mostly, it is due to infectious causes and regarded as a benign and self-limiting condition particularly in younger patients. Patients above 40 years of age and those with high risk factors require thorough evaluation. Detailed examination is mandatory, and should include: blood pressure measurement and abdominal palpation to identify hepatosplenomegaly or renal enlargement. Genital examination must also be performed to assess for the presence of testicular lumps and urethral discharge, as well as a rectal examination to assess the prostate. Further investigations include cystoscopy, transrectal ultrasound, and prostate biopsy. Diagnosing prostatic pathologies is made easier by performing transrectal ultrasound. It is useful in diagnosing calculi, cysts, prostatic varices, and inflammatory changes, as well as therapeutic in certain cases where cyst or abscess is drained and is found to be the cause of hematospermia. Complex investigations depend on history and examination. A role of MRI is emerging to rule out rare causes of hematospermia. Evidence based evaluation of hematospermia is not only useful in definitive diagnosis, but it can also be cost effective. Therefore, we suggest that patients with high risk factors should be investigated thoroughly. However, younger patients with one episode can be monitored closely and investigated only if deemed necessary.

**Key Words:** hematospermia ◊ differential diagnosis ◊ treatment

## INTRODUCTION

Hematospermia, or hemospermia, is defined by the presence of blood in ejaculate. It is usually an isolated symptom; however, it can present in association with hematuria, frequency, dysuria, and/or scrotal pain [1, 2]. It often invokes considerable anxiety and is frightening to the patient. Hematospermia has been regarded as a benign and self-limiting condition [3]. It is most often due to inflammatory or infectious causes. Recurrent or persistent hematospermia, however, may indicate a more serious underlying pathology, especially in patients over 40 years of age and such patients should be referred to a urologist for consultation.

## Incidence

Currently, the exact incidence of hematospermia is unknown due to the fact that most men do not examine their semen, and consequently do not report for consultation. Although an incidence of hemato-

spermia has been reported as one in every 5,000 new patients presenting to urological out-patient clinics. Most often the age range of these patients is between 30 and 40 years, but men over 40 also present with this symptom [4]. At this time there are no set guidelines regarding the evaluation of such patients with hematospermia that would allow a definitive diagnosis, and only limited evidence is available.

## CAUSES

Traditionally, blood in ejaculate was considered clinically insignificant and presumed secondary to prolonged sexual abstinence or intense sexual experiences. The exact cause of hematospermia cannot be found in as many as 70 percent of patients.

In most cases hematospermia is idiopathic. A single episode of hematospermia is usually considered benign and the risk of malignancy is low [5]. However, persistent or recurrent symptoms of hematospermia can be very stressful for a patient. This is

unsatisfactory for both the patients and urologists if the cause of hematospermia remains unknown. In such cases systematic investigations are required to establish a diagnosis and commence etiological treatment.

Infection or inflammation is considered to be the main culprit in cases of hematospermia and in most cases is found to be self-limiting. Neoplasms such as benign urethral tumor or seminal vesicle malignancy can present as hematospermia [6, 7]. Hematospermia is usually a symptom of a urological problem, however, other medical conditions or systemic diseases such as malignant hypertension, liver dysfunction, or bleeding diathesis may be the cause.

### Baseline investigations

Hematospermia remains a symptom that is difficult to treat, especially if it is recurrent or persistent in nature. Most often the causes of hematospermia are idiopathic and only simple investigations are required for evaluation [3]. The patient's age, recurrence of hematospermia, and associated urinary symptoms, e.g. hematuria, can influence decisions for further evaluation. The aim of all investigations in such cases of the hematospermia should be focused on determining its cause or to rule out infection and malignancy. The evaluation of hematospermia requires a detailed anamnesis, physical examination, and appropriate investigations.

**Table 1. Causes of hematospermia**

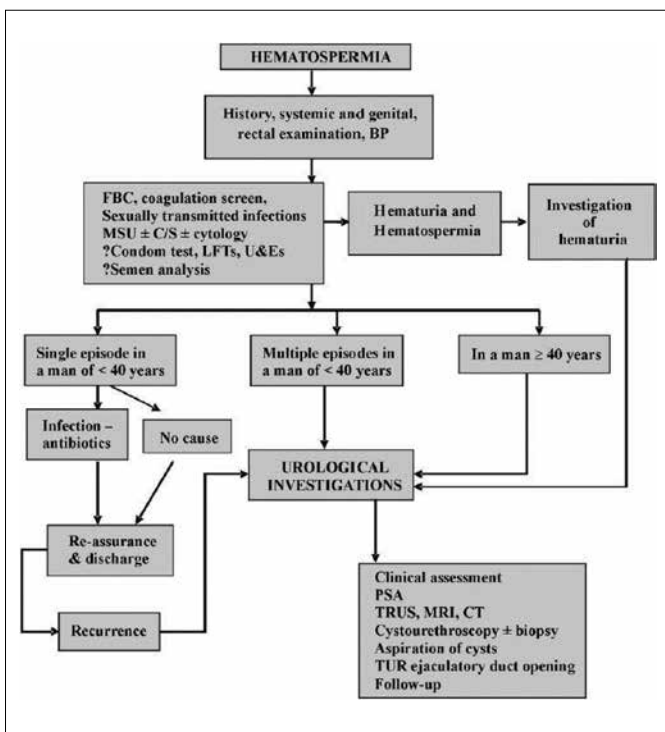
Sexually transmitted diseases such as: Herpes simplex virus, <i>Escherichia coli</i> , <i>Ureaplasma urealyticum</i> , and <i>Chlamydia trachomatis</i>
Trauma, following transrectal ultrasound guided prostate biopsy (iatrogenic), blunt perineal trauma, hemorrhoidal injection, or brachytherapy
Prostatic diseases such as: acute/chronic bacterial prostatitis, benign prostatic hyperplasia, prostatic calculi, and abnormal prostatic urethral vessels
Systemic disease such as: severe uncontrolled hypertension, bleeding disorders, or amyloidosis (rare)
Testicular or epididymal conditions such as: orchitis, epididymitis, or testicular trauma
Seminal vesicle disorders such as: asymmetric dilatation, cyst, or calculi
Chronic infections: such as: tuberculosis or schistosomiasis
Ejaculatory ducts disorders such as: cyst, calculi, or müllerian duct cyst
Malignant:
Prostate cancer, testicular/epididymal tumors, seminal vesicle carcinoma (rare), or urethral tumor

An important step in during anamnesis is to exclude pseudo-hematospermia, which could be due to hematuria or even suction of a partner's blood into the urethra during copulation. The anamnesis in case of hematospermia should include the timing, frequency, and associated symptoms. Likewise, the interviewing physician should rule out other possible precipitating factors such as urethral discharge, history of sexually transmitted disease (STD), odynorgasmia, and vascular or bleeding diatheses [8]. Other co-existing systemic diseases, i.e. hypertension, liver problems, or coagulopathies, should also be excluded [9]. The patient's travel history is also very important, especially in the case of tuberculosis or schistosomiasis.

A detailed physical examination is also mandatory and should include blood pressure readings and abdominal palpation to assess for hepatic, splenic, or renal enlargement. Genital examination is compulsory and should assess the testicles for lumps, identify urethral discharge, and recognize prostatic abnormalities.

Other simple investigations may include urine microscopy, sperm culture, PSA levels, and presence of STD. A transrectal ultrasound and possibly prostate biopsy are indicated in case of high PSA levels or suspicious findings of the prostate or seminal vesicles during rectal examination. Further tests depend on history and may include coagulation studies in cases of bruising or bleeding tendencies.

Following the correct execution of the abovementioned studies, very few patients will still require further investigations to rule out other causes. How-



**Figure 1.** Flow chart; management of hematospermia.

ever, urethroscopy will also be useful to rule out urethral or bladder malignancy in patients with hematuria. Also, complex cases, such as urethral varices often require careful evaluation and possibly diathermic coagulation. Furthermore, patients with persistent hematospermia may benefit from transurethral seminal vesiculoscopy [11].

In the vast majority of cases, it should be noted that the hematospermia resolves by the time the patient is seen in the urology clinic. If the patient has no risk factors, he should be discharged with a reassuring explanation for the cause of his symptoms. However, patients with high-risk factors or other associated symptoms should be investigated accordingly.

### Diagnostic imaging

Transrectal ultrasound (TRUS) has been found to be helpful in the diagnosis of prostatic pathologies, as well as calculi, cysts, prostatic varices, and inflammatory changes. It is also therapeutic in certain cases where cyst or abscess is drained and is found to be the cause of hematospermia. An urgent ultrasound should be organized in the case of a testicular lump, as this could be the cause of blood in the ejaculate [10].

We would also like to mention that the role of MRI studies is emerging with the recent suggestion that endorectal MRI should be considered the 'evaluation modality of choice' in patients with persistent hematospermia [12]. The MRI has also been reported as sensitive in the detection of bleeding in the seminal vesicles in patients with hematospermia [12]. In case of recurrent hematospermia, MRI and CT may be useful in finding the cause [13]. Any further investigations depend on the outcome of clinical evaluation.

### Treatment of hematospermia

In the majority of cases, a firm reassurance is particularly sufficient in patients with minimal risk factors aged below 40 years. The main purpose of the numerous investigations mentioned above is to exclude serious conditions such as cancer of the bladder or prostate. If the condition is found to be idiopathic, it is important to thoroughly explain the situation to the patient in detail in order to alleviate his anxiety. Hematospermia can be safely managed at the patient's primary care facility and referrals for further urological consultation regarding this matter should only be made in case of abnormal findings on examination, elevated PSA, and/or recurrent symptoms [5]. Patients with hematospermia and high-risk factors, i.e. aged over 40 years, recurrent or persistent

hematospermia, hematuria, or familial history of PCa, require more extensive evaluation and should be referred to a urologist for specialist consultation. However, in the absence of any obvious cause the treatment of hematospermia becomes challenging [11].

When treatment is deemed necessary it should be directed by the diagnosed etiology. Cases of suspected STD should be evaluated at a genitourinary medicine [GUM] clinic and, if the infection is confirmed, should be treated according to the etiology. The most common pathogens in such cases are *Chlamydia*, gonorrhea, and herpes simplex, all of which can be treated with a course of antibiotic therapy. If cultures are negative, but infection is still suspected then a course of doxycycline in combination with either a 5-aminoquinolone or sulfamethoxazole may be effective [3].

Patients presenting with hematospermia secondary to trauma can most often be assured that their condition will improve with time. A cystoscopy can reveal abnormal urethral and/or prostatic vessels, which can be treated using endoscopic fulguration [14]. Also, a TRUS-guided transperineal seminal vesicle puncture and continuous irrigation with antibiotics has shown improvement in 90% of cases [15]. Ejaculatory duct obstruction is managed by performing a transurethral incision at the duct opening [16].

The rarity of hematospermia in congenital bleeding disorders remains unexplained, although the strong perineal and sphincter muscles may exercise a compressive hemostatic effect that could prevent or reduce bleeding [17]. Systemic disorders such as tuberculosis, hepatic cirrhosis, hypertension, amyloidosis, and coagulation disorders should be dealt appropriately.

Persistent hematospermia is difficult to deal with from a management perspective, however, a detailed radiological assessment may ascertain the exact cause. It is also important to keep these patients under follow-up for a limited period of time. In some patients, persistent or recurrent hematospermia could be the only symptom of PCa. In high-risk individuals, those in middle age, or those with a familial history of PCa, surveillance with PSA observation over a period of time is desirable.

## CONCLUSIONS

Hematospermia can have significant psychological and clinical implications. In younger patients with low risk factors, most of the causes are idiopathic and benign. However, hematospermia needs careful and thorough investigations in men aged over 40 years, especially those with high risk factors. Evidence-based evaluation of hematospermia is not only useful

in making definitive diagnoses, but can also reduce unnecessary hospital visits. Therefore, we suggest that patients with high risk factors should be inves-

tigated thoroughly, however, younger patients with a single episode can be monitored closely and investigated if necessary.

## References

- Weidner W, Jantos C, Schumacher F, Schiefer HG, Meyhöfer W. Recurrent haemospermia. Underlying urogenital anomalies and efficacy of imaging procedures. *BJUrol*. 1991; 67: 317–323.
- Jones DJ. Haemospermia: a prospective study. *BJUrol*. 1991; 67: 88–90.
- Kumar P, Kapoor S, Nargund V. Haemospermia, a systemic review. *Ann R Coll. Surg Engl* 2006; 88: 339–342.
- Leary FJ, Auguilo JJ. Clinical significance of heamospermia. *Mayo Clin Proc*. 1974; 49: 815–817.
- Wilson C, Boyd K, Mohammed A, Little B. A single episode of haemospermia can be safely managed in the community. *Int J Clin Pract*. 2010; 64: 1436–1439.
- Gattoni F, Avogadro A, Sacrini A, Blanc M, Pozzato C, Spagnoli I, Uslengih C. Transrectal prostate echography in the study of hemospermia. An assessment of an 85 patient caseload. *Radiol Med*. 1996; 91: 424–428.
- Papp GK, Hozme K, Hegedus A. Hemospermia. *J Androl*. 1994; 15: 315–335.
- Narouz N, Wallace DM. Hemospermia: in the context of genitourinary medicine setting. *Int J STD AIDS* 2002; 13: 517–521.
- Bhaduri S, Riley VC. Hemospermia with malignant hypertension. *Sex Transm Infect*. 1999; 75: 200.
- Maheshkumar P, Otite U, Gordon S, Berney DM, Nargund VH. Testicular tumour presenting as hemospermia. *J Urol*. 2001; 165: 188.
- Coppen L. Diagnosis & treatment of obstructive seminal vesicle pathology. *Acta Urol Belg*. 1997; 65: 11–19.
- Prando A. Endorectal magnetic resonance imaging in persistent hemospermia. *Int Braz J Urol*. 2008; 34: 171–177.
- Maeda H, Toyooka N, Kinukawa T, Hattori R, Furukawa T. Magnetic Resonance image of haemospermia. *Urology*. 1993; 41: 499–504.
- Redman JF, Young JW. Massive post-ejaculation hematuria. *Urology*. 1987; 30: 73.
- Zhang XR, Baojun GU, Yuemin XU, Chen R, Zhang J, Qiao Y. Transrectal ultrasonography-guided transperineal bilateral seminal vesicle puncture and continuous irrigation for the treatment of intractable hemospermia. *Chin Med J*. 2008; 121: 1052–1054.
- Fuse H, Nishio R, Murakami K, Okumura A. Transurethral incision for hemospermia caused by ejaculatory duct obstruction. *Arch Androl*. 2003; 49: 433–438.
- Girolami A, Scarparo P, Candeo N, Satori R, Scandellari R, Girodani B. Hemospermia in patients with congenital coagulation disorders: a study of three cases. *Acta Haematol*. 2009; 121: 42.