

Anastomosing hemangioma with fatty changes of the genitourinary tract: a lesion mimicking angiomyolipoma

Tien Anh Tran, Peter Pernicone

Department of Pathology, Florida Hospital Orlando, FL, USA

KEY WORDS

anastomosing hemangioma ▶ fatty changes ▶ angiomyolipoma

ABSTRACT

Anastomosing hemangioma of the genitourinary tract is a recently described vascular lesion of the kidneys and testes. Although these lesions can occur in the renal hilum with infiltration of the hilar adipose tissue, the presence of adipocytes in this type of vascular tumor has not been reported. We described a case of an anastomosing hemangioma associated with fatty changes of the stromal component in a 59-year-old female patient. This unusual morphologic finding not only represents a novel curiosity in this rare type of vascular lesion, but also could potentially pose significant diagnostic challenges as it is commonly mistaken as an angiomyolipoma.

INTRODUCTION

Vascular lesions of the kidney are relatively rare and have only been documented predominantly in the form of case reports and small series [1-4]. A recent large series of vascular lesions in the kidney documented a spectrum of morphologic findings ranging from arteriovenous malformations and hemangioma to angiosarcomas, while hemangioma was the most common vascular tumor of this organ [5]. Some of these hemangiomas exhibited a unique architecture reminiscent of the sinusoidal pattern of the spleen. Elizabeth Montgomery and Jonathan I. Epstein proposed the term "anastomosing hemangioma of the genitourinary tract" for this subset of hemangioma [7]. We recently encountered an unusual variant of renal anastomosing hemangioma showing fatty changes that could potentially pose significant diagnostic challenges.

CASE REPORT

The patient was a 61-year-old male patient with a long history of right-sided back pain with radiation to his right hip. To evaluate the etiology of his back pain, an abdominal ultrasound was performed in an outside institute and revealed a right renal mass. A subsequent CT scan demonstrated a 2.4 x 2.1 cm right renal cortical mass in the mid to upper pole that protruded into the renal sinus and showed heterogeneous enhancement (Fig. 1). The tumor appeared to displace the renal calyces. By contrast view, the mass appeared to be adjacent to but separate from the collecting system.

Additional staging did not detect any other lesions. The patient's family history was significant for metastatic renal urothelial carcinoma in his mother. The patient was transferred to our hospital for further treatment.

Since the mass was located between the bifurcation of the right renal artery it made a partial nephrectomy difficult and the patient underwent a right hand-assisted laparoscopic radical nephrectomy, which revealed a 2.1 cm circumscribed spongy-red mass in the hilar sinus fat of the superior pole of the right kidney. Focal, apparent extension into a portion of the renal vein was grossly noted.

Under low power examination, the lesion was well circumscribed and appeared encapsulated (Fig. 2 a). The wall-like capsule was composed predominantly of smooth muscle as highlighted by immunohistochemistry for smooth muscle actin. However, the capsule was devoid of elastic fibers and internal elastic lamina based on evaluation of Verhoeff's elastic stain. The tumor was composed of dilated sinusoidal capillary-like vessels that were lined by hobnail endothelial cells with a mild degree of nuclear atypia (Fig. 3B). Rare medium-sized vessels with thick muscular walls were present at the periphery of the tumor. Fibrin thrombi and extramedullary hematopoiesis were easily identified in the lumen of the small vessels (Fig. 3 a and 3 b). In several areas, the architecture of the capillary-like vessels was reminiscent of splenic parenchyma (Fig. 3 a). A small focus of intravascular extension was observed at the periphery of the tumor (Fig. 4). The central portion of the tumor appeared sclerotic and edematous. Of interest was the presence of several clusters of fat cells distributed throughout the lesion (Fig. 2 b). Immunohistochemical studies for CD31 and Factor VIII highlighted the extensive endothelial cell-lined vascular network.

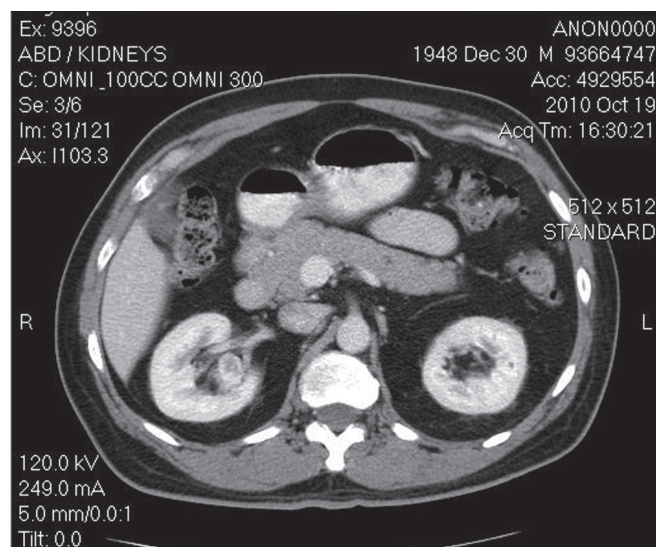


Fig. 1. Abdominal CT scan with a right renal sinus mass showing heterogeneous enhancement.

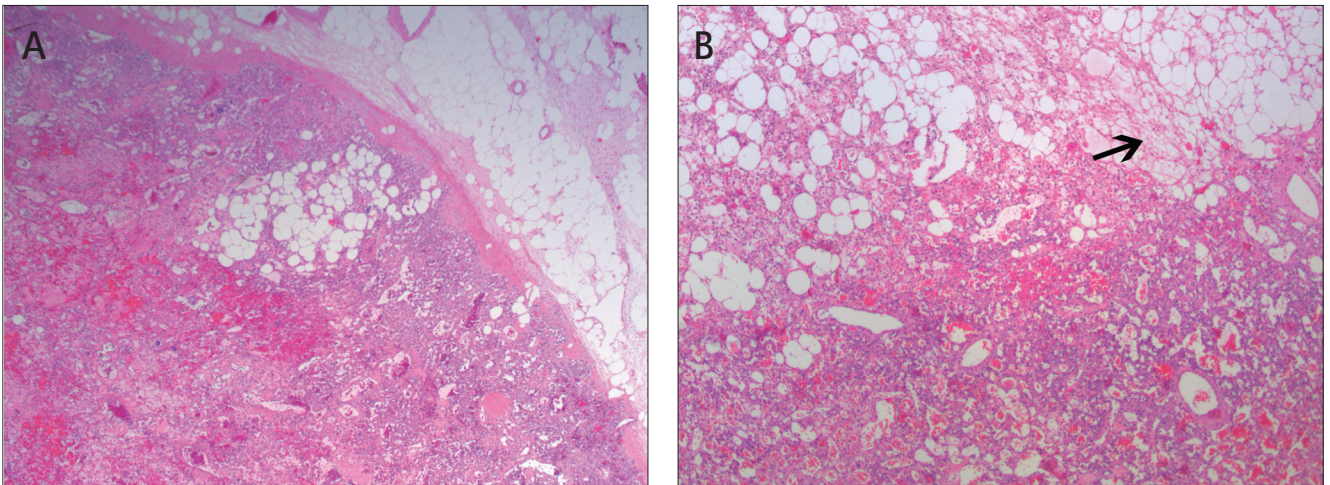


Fig. 2 A, B. Encapsulated tumor, well demarcated from surrounding adipose tissue of the renal hilum (2A, x 20) with clusters of fat cells (arrow) between the vascular channels (2B, x 40) (H & E stain).

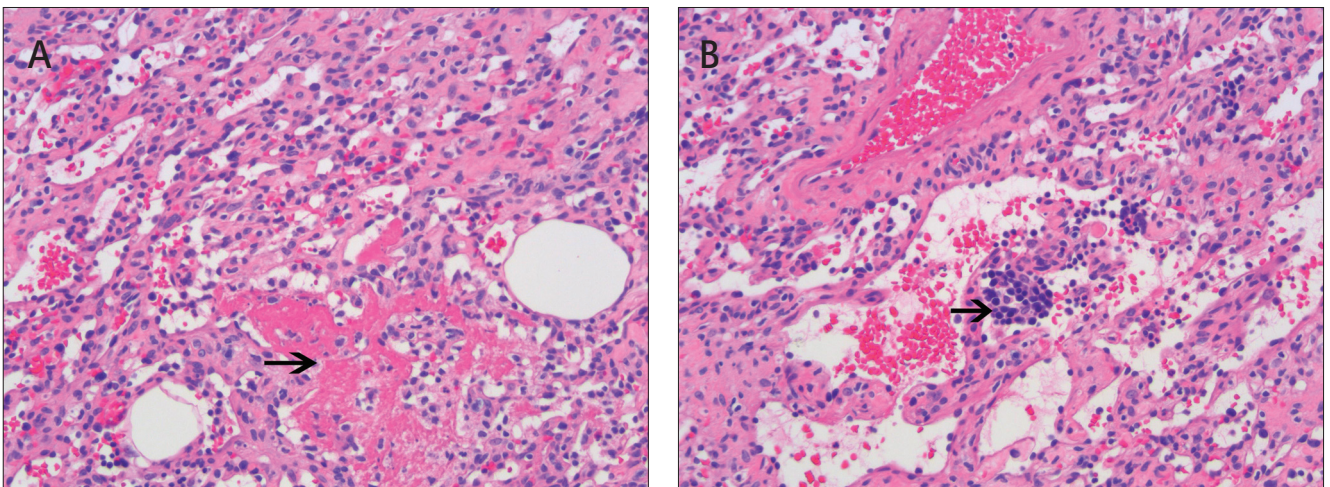


Fig. 3 A, B. Sinusoidal capillary-sized vessels lined by hobnail endothelial cells with intravascular fibrin thrombi (3A, x 200) and extramedullary hematopoiesis (3B, x 200). Note the spleen-like architecture of the tumor (H & E stain).

The tumor demonstrated no immunoreactivity for Melan-A, HMB-45, and EMA. Although the tumor was negative for S-100 protein, the fat cells were strongly positive for this antibody. The overall histologic and immunohistochemical findings of the tumor were consistent with those of an anastomosing hemangioma of the genitourinary tract with fatty changes.

DISCUSSION

Hemangioma is the most common vascular lesion in the kidney as documented in a recent large study of vascular lesions of the kidney [5]. Most of them were located in the renal hilum and well demarcated, although unencapsulated. In that study, a subset of renal hemangiomas of the kidney demonstrated a sinusoidal spleen-like architecture. The morphologic resemblance of this vascular lesion to sinusoidal architecture of the splenic red pulp prompted Drs. Elizabeth Montgomery and Jonathan E. Epstein to coin the term "anastomosing hemangioma of the genitourinary tract" for this type of vascular lesion, believed to be unique for the genitourinary system [6]. The authors presented a series of 6 peculiar vascular tumors in the kidney and testes with unusual histologic features characterized by anastomosing capillary-sized vessels lined by scattered hobnail endothelial cells, zones of central sclerosis and necrosis, intraluminal thrombi and extramedullary hematopoiesis, and spleen-like areas. Whereas all

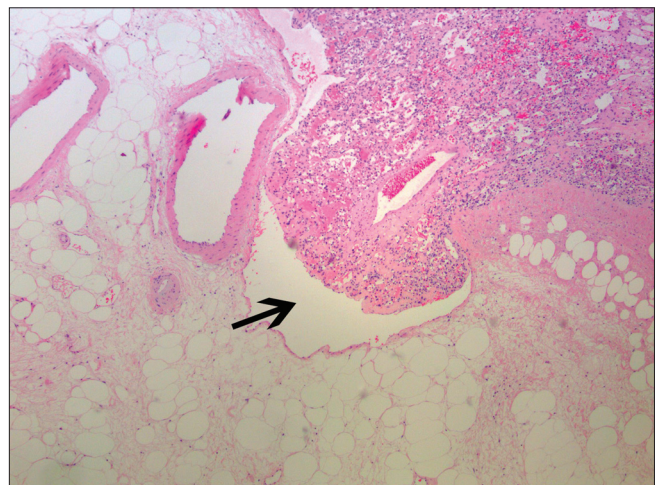


Fig. 4. Focal intravascular extension (x 40) (H & E stain).

3 tumors located in the perirenal adipose tissue exhibited an infiltrative periphery, at least focally, both testicular lesions appeared well circumscribed and sharply demarcated from the surrounding parenchyma.

Although our tumor is located in the hilar adipose tissue, it is well circumscribed and encapsulated. The wall-like capsule is com-

posed predominantly of smooth muscles, raising the possibility that the tumor is intravascular in origin. However, an elastic stain displays neither elastic fibers nor an internal elastic lamina, thus ruling out an intravascular origin of this tumor. Another unusual histologic finding is the presence of fat in the lesion, which has not been reported in the literature. This morphologic finding not only represents a novel curiosity in this rare type of vascular lesion, but could potentially pose significant diagnostic challenges, namely, in misdiagnosing the lesion as an angiomyolipoma due to the combination of adipose tissue, medium-sized vessels with thick muscular wall, and capillary-like vascular channels. In their original studies, Drs. Elizabeth Montgomery and Jonathan E. Epstein included various forms of vascular tumors in the differential diagnosis, but did not mention angiomyolipoma as a potential mimicker of anastomosing hemangioma. Histologic clues that are helpful in differentiating anastomosing hemangioma from angiomyolipoma are the presence of abundant sinusoidal capillary-like vessels (which imparts more of a vascular appearance on low power), the observation of fibrin thrombi and extramedullary hematopoiesis, and the foci of intravascular extension. All these histologic features are rarely seen in a typical angiomyolipoma, particularly simultaneously in the same lesion. In particular, the finding of extramedullary hematopoiesis appears to be an extremely rare phenomenon in renal angiomyolipoma. In fact, extramedullary hematopoiesis was not recorded in any case in two recent large studies of renal angiomyolipoma [7, 8]. Immunohistochemical studies with Melan-A and HMB-45 can be of great assistance in difficult cases since anastomosing hemangioma is negative for these antibodies whereas angiomyolipoma should be immunoreactive, at least, focally.

Review of the literature revealed a single case report of renal angiomyolipoma with extramedullary hematopoiesis [9]. Interestingly, the renal angiomyolipoma in that case report demonstrated a prominent angiomatous component characterized by "striking proliferation of monotonous ovoid endothelial cells forming vascular channels, anastomosing cords and sheets". Immunohistochemical studies with HMB-45 or Melan-A were not performed. In our opinion, the "renal angiomyolipoma with a prominent angiomatous component and extramedullary hematopoiesis" in that case report most likely represented another example of an anastomosing hemangioma of the genitourinary tract with fatty changes. Similar to our case, the renal angiomyolipoma with extramedullary hematopoiesis in that case report was also grossly well circumscribed, although unencapsulated.

In summary, we report a variant of renal anastomosing hemangioma with fatty changes, which broadens the histologic spectrum of this uncommon vascular lesion of the genitourinary tract. Since the biologic nature of anastomosing hemangioma is still indeterminate due to the short clinical follow-up in most cases, awareness of this unusual variant of anastomosing hemangioma may be of clinical importance to avoid confusing it with a typical angiomyolipoma.

REFERENCES

- Costa Neto TF, Renteria JM, Di Biase Filho G: *Renal hemangioma*. Int Braz J Urol 2004; 30: 216-218.
- Jahn H, Nissen HM: *Haemangioma of the urinary tract: review of the literature*. Br J Urol 1991; 68: 113-117.
- Leggio L, Addolorato G, Abenavoli L, et al: *Primary renal angiosarcoma: a rare malignancy. A case report and review of the literature*. Urol Oncol 2006; 24: 307-312.
- Terris D, Plaine L, Steinfeld A: *Renal angiosarcoma*. Am J Kidney Dis 1986; 8:131-133.
- Brown JG, Folpe AL, Rao P, et al: *Primary vascular tumors and tumor-like lesions of the kidney: a clinicopathologic analysis of 25 cases*. Am J Surg Pathol 2010; 34: 942-949.
- Montgomery E, Epstein JI: *Anastomosing hemangioma of the genitourinary tract: a lesion mimicking angiosarcoma*. Am J Surg Pathol 2009; 33: 1364-1369.
- Aydin H, Magi-Galluzzi C, Lane BR, et al: *Renal angiomyolipoma: clinicopathologic study of 194 cases with emphasis on the epithelioid histology and tuberous sclerosis association*. Am J Surg Pathol 2009; 33: 289-297.
- L'Hostis H, Deminiere C, Ferriere JM, Coindre JM: *Renal angiomyolipoma: a clinicopathologic, immunohistochemical, and follow-up study of 46 cases*. Am J Surg Pathol 1999; 23: 1011-1020.
- Lin CN, Chiang HS, Hsu SI, et al: *Renal angiomyolipoma with a prominent angiomatous component and extramedullary hematopoiesis: a case report*. Zhonghua Yi Xue Za Zhi (Taipei) 1994; 53: 185-187

Correspondence

Tien Anh Tran
 Department of Pathology
 Florida Hospital Orlando
 610, East Rollins Street
 Orlando, Florida 32803, USA
 phone: +407 303 9397
 trannguyentienanh@hotmail.com