

Management of encrusted ureteric stent and impacted stone in pregnancy – a challenging dilemma

Faisal Rauf Khan, Ahmed Mabrouk Alost, Samer Katamawi Sabbagh, Sardar Zeb Khan, Roland England, Muhammad Al-Sudani

Urology Registrar, Kettering General Hospital, Kettering, United Kingdom

KEY WORDS

pregnancy ▶ stone ▶ X-ray radiation

ABSTRACT

We are presenting an interesting case of impacted stone and stent in a pregnant patient. We have proved safe use of ureteroscopy and laser in pregnancy with minimal x-ray exposure.

INTRODUCTION

Urinary stones are rare and challenging in pregnancy with an incidence of 1 in 1500 pregnant women [1]. There is always a danger of x-ray exposure to the fetus and high mortality and morbidity to females with infective obstruction or with invasive treatment. Decisions to treat pregnant patients with symptomatic stones should be made very carefully and critically.

We present a difficult case of managing renal stone in pregnancy that required a multi-disciplinary approach involving different departments including those of radiology, anesthesiology, gynecology, and urology. We proved the safe use of lasers in pregnancy for ureteric stones. This case report also highlights the importance of multi disciplinary teams involvement for better outcome for mother and baby.

PATIENT AND METHODS

A 21-year-old female patient was admitted with left renal colic. CT scan revealed 11 mm left upper ureteric stone. Emergency ureteric JJ stenting was done and the patient was discharged with a plan for elective ureteroscopy and stone fragmentation. While waiting for stone management, she became pregnant. She was 14 weeks pregnant when she required admission for severe left sided renal colic and urinary tract infection. Inflammatory markers were raised and ultrasound scan reported a moderate left hydronephrosis.

After a discussion in the x-ray meeting, the plan was to exchange the JJ stent under ultrasound guidance and local anesthesia. After discussion with the patient, she claimed severe irritation from the JJ stent and asked for complete removal without exchange.

During flexible cystoscopy, the encrusted stent was difficult to remove. The procedure was stopped and she was taken to the operating theater the next day. Anesthetists and gynecologists were involved. A rigid ureteroscopy and laser lithotripsy of the stone and encrusted stent was performed without using any imaging. The replacement stent was not inserted as requested by the patient.

Post operatively, both mother and fetus were normal. Unfortunately, four days post operatively; she was pyrexial and in pain. Ultrasound revealed worsening of hydronephrosis and dila-

tation of the upper ureter. Emergency nephrostomy was inserted and she was discharged home. She revisited A&E twice for blocked nephrostomy, which were flushed. As she was struggling with her nephrostomy, a trial of clamping was planned. Luckily good drainage occurred and ultrasound showed no significant hydronephrosis, therefore the nephrostomy was removed. She was feeling well at the time of discharge.

DISCUSSION

Urolithiasis is derived from Greek word meaning urinary stone. It is considered to be the most common cause of abdominal pain and hospital admission in pregnant ladies after excluding obstetrical causes [2]. However, the relative incidence and rate of recurrent stones in pregnant patients are the same to non-pregnant females [3].

No exact cause for the formation of urinary stones in pregnancy is known.

Different hypotheses are available in the literature. Anatomic, physiological, and volume changes in pregnancy are considered as the culprits for stones formation. Physiological hydronephrosis, decreased ureteral peristalsis, and infections are also considered as predisposing factors. Diagnosis of renal stones is not difficult in this era of computed tomography (CT) scan. But unfortunately we have to limit x-ray radiation for the safety of the fetus.

Ultrasound is the best and most favorite investigation for renal stones in pregnancy.

Vaginal ultrasound is helpful in diagnosing lower ureteric stone while color Doppler is reported to have 100% sensitivity in picking ureteral obstruction [4]. There is evidence of using limited

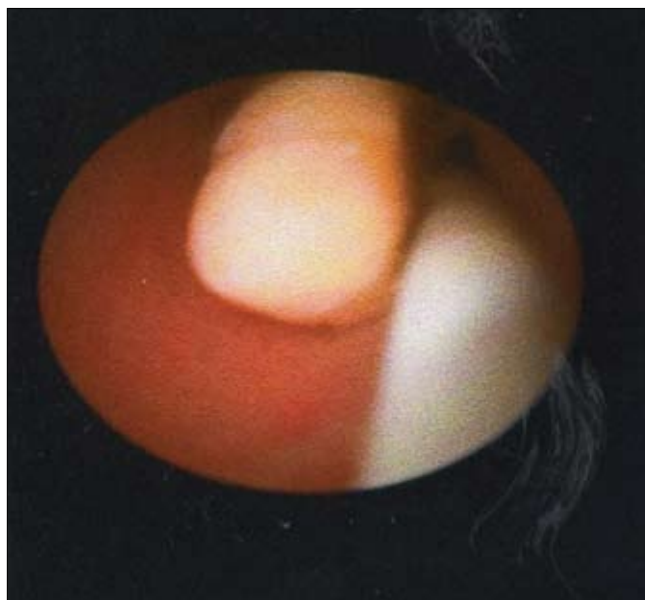


Fig. 1. Stone with stent in ureter.

Intravenous Urography, magnetic resonance imaging, nuclear renal scan, and low dose CT scan in diagnosing renal stone. However, any study that involves radiation should be avoided when possible, and should be discussed with patients.

Most of the stones are small and treated conservatively. Larger stones that present as emergencies are initially treated with stent insertion to relieve pain followed by de-obstruction of the kidney. JJ stents can be left for 3-4 months while waiting for the proper treatment i.e ureteroscopy or some kind of intervention. Our patient was not pregnant at the time of initial presentation. However while waiting for ureteroscopy she was pregnant.

Expulsive therapy like calcium channel blockers, alpha adrenoceptor blockers and steroids, are contraindicated during pregnancy [5]. If conservative treatment fails, percutaneous nephrostomy or JJ stent could be considered.

Ureteroscopy with stone retrieval is now considered the procedure of choice.

It is considered diagnostic as well as therapeutic. It is considered as safe with stone-free rates between 70% and 100% [6]. It can be performed under general, spinal, local anesthesia or even with sedation and majority of them can be performed with minimal or without ionizing radiation. Stone fragmentations have been performed using lasers, lithoclast, basket retrieval, and forceps crush [7].

Different lasers such as holmium:YAG (yttrium-aluminium-garnet) and pulsed dye lasers are used in pregnancy. The holmium YAG laser has a high safety margin and can be used for all types of stones as well as can be used in both rigid and flexible ureteroscopes. The energy generated by the YAG laser can not transmit from the patient to the fetus, and thus reducing the risk of damaging to the fetus in comparison with electrohydraulic probes [8].

CONCLUSION

The following points have been clearly demonstrated with evidence based on the discussion in the above case:

- a. There is significance to a multidisciplinary approach in managing symptomatic stones in pregnancy for a better outcome.
- b. Exposure to radiation should be limited during pregnancy.
- c. The safe use of ureteroscopy and laser without using fluoroscopy to achieve stone free status.
- d. Stone-free results can be achieved during pregnancy with treatments avoiding long-term nephrostomy and its unwanted side effects.

REFERENCES

1. Buchholz NP, Biyabani R, Sulaiman MN, Talati: *Urolithiasis in pregnancy: a clinical challenge*. Eur J Obstet Gynecol Reprod Bio Sep 1998; 80 (1): 25-29.
2. Folger GK: *Pain and pregnancy; treatment of painful states complicating pregnancy, with particular emphasis on urinary calculi*. Obstet Gynecol 1955; 5 (4): 513-518.
3. Drago JR, Rohner TJ: *Chez RA Management of urinary calculi in pregnancy*. Urology 1982; 20 (6): 578-581.
4. Shokeir AA, Abdulmaaboud M: *Resistive index in renal colic: a prospective study*. BJU Int 1999; 83 (4): 378-382.
5. Singh A, Alter HJ: *A systematic review of medical therapy to facilitate passage of ureteral calculi*. Ann Emerg Med 2007; 50: 552-563.
6. Ulvik NM, Bakke A, Hoisaeter PA: *Ureteroscopy in pregnancy*. J Urol 1995; 154: 1660-1663.
7. Akpinar H, Tüfek I, Alici B, Kural AR: *Ureteroscopy and holmium laser lithotripsy in pregnancy: Stents must be used postoperatively*. J Endourol 2006; 20: 107-110.
8. Karlsen SJ, Bull-Njaa T, Krokstad A: *Measurement of sound emission by endoscopic lithotriptors: An in vitro study and theoretical estimation of risk of hearing loss in a fetus*. J Endourol 2001; 15: 821-826.

Correspondence

Faisal Rauf Khan
Urology Registrar
Kettering General Hospital
Rothwell Road
Northamptonshire, NN16 8UZ
Kettering, UK
phone: +44 1536 493 674
f.khan@doctors.org.uk