

Extracorporeal shockwave lithotripsy in the treatment of encrusted ureteral stents

Catalin Pricop¹, James C. Williams JR², Catalin Ciuta¹, Dan Mischianu³

¹University of Medicine and Pharmacy "Gr T Popa" Iasi, Clinical Hospital "Dr. CI Parhon" Iasi, Clinic of Urology and Renal Transplantation, Iasi, Romania

²Department of Anatomy and Cell Biology, University of Indiana, USA

³University of Medicine and Pharmacy Bucharest, Clinic of Urology, Central Military Hospital, Bucharest, Romania

KEY WORDS

ESWL ▶ encrusted ureteral stent

ABSTRACT

Introduction. Forgotten, encrusted ureteral stents represent a difficult problem for urologists, and a consensus on the best therapeutic approach is lacking.

Material and methods. We present a case of a female patient who was treated for an encrusted ureteral stent using extracorporeal shockwave lithotripsy.

Conclusion. Successful management of encrusted ureteral stents requires careful planning and may entail a combination of endourologic approaches. It is imperative to avoid using significant force, which can result in severe ureteral injury or breakage of the stent. We believe in treating the distal component prior to managing any proximal or ureteral components and extracorporeal shockwave lithotripsy is the first choice to choose.

INTRODUCTION

The use of ureteral stents has greatly changed the treatment of urinary lithiasis, bringing a new solution for urological emergencies and allowing for a free spell till the specific treatment of the culpable stone [9]. In contact with the urine, the stents are quickly covered with a bacterial microfilm (biofilm) and, most frequently, with mineral and organic encrustations, which may lead to new stones [7]. A variety of factors contribute to the rate at which this process occurs, including the material of the stent or catheter, urine composition, and duration of contact of the drain with urine [7]. The evolution of these new stones is unpredictable leading to an encrusted stent which is difficult and sometimes impossible to draw out [1, 4]. The forgotten stent may be asymptomatic and "remembered" only when its presence is incidentally revealed by abdominal imaging. Conversely, a patient with ureteral obstruction from an encrusted stent can present with life-threatening urosepsis, which may be lethal in some cases [8]. We present the case of a patient who had an encrusted stent that was impossible to extract after six weeks of use, requiring extracorporeal shockwave lithotripsy (ESWL) to resolve the problem.

CASE REPORT

We present the case of a 45-year-old Caucasian, with significant lithiasis history (2000 – bilateral percutaneous neph-

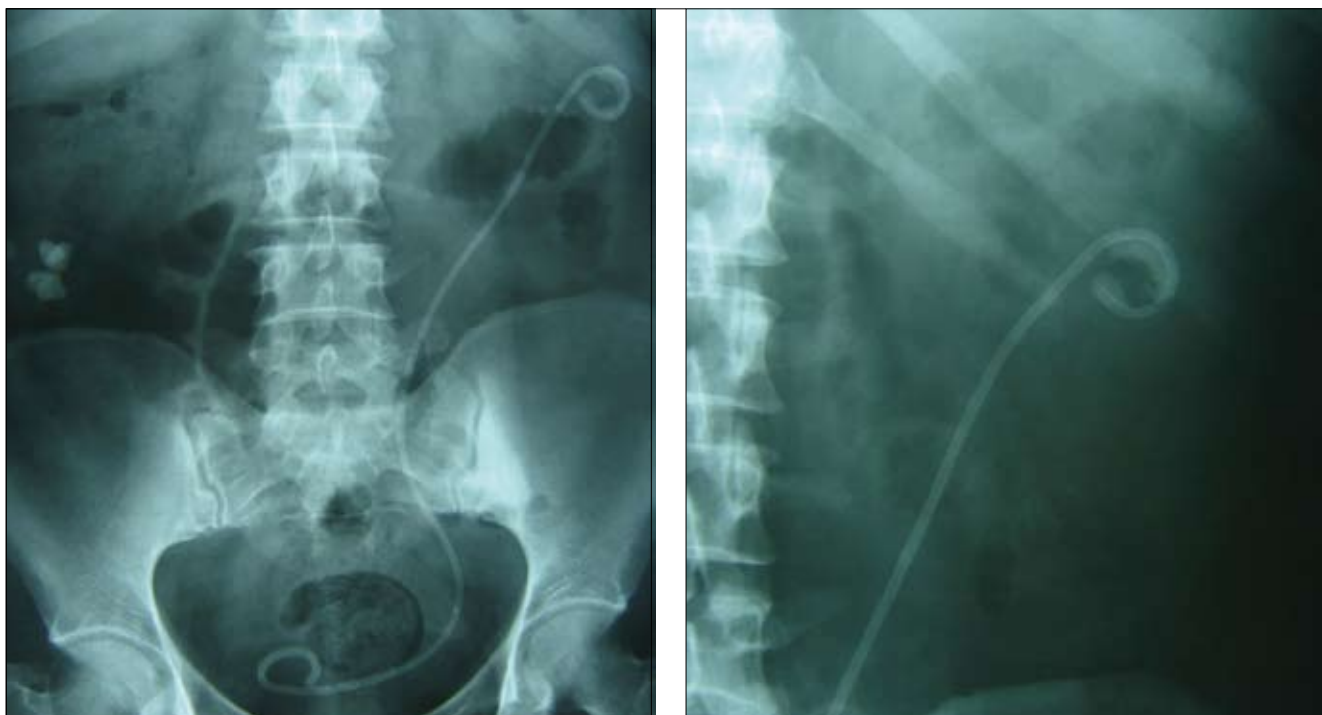


Fig. 1. Plain abdominal radiography – encrusted ureteral double J stent.

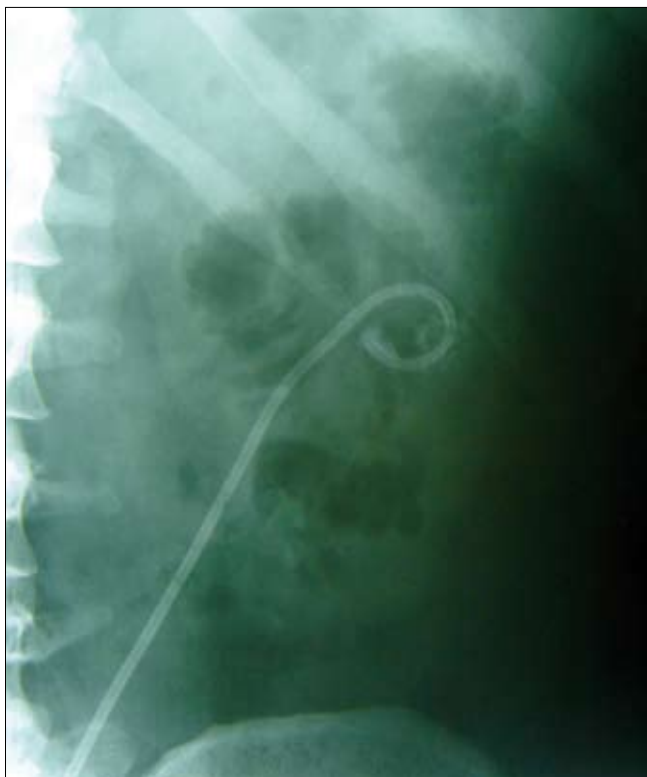


Fig. 2. Plain abdominal radiography - ureteral double J stent post-ESWL.

rolithotomy for bilateral pyelocaliceal stones, 2002 – left ureteroscopy for an iliac ureteral stone, 2006 – right percutaneous nephrolithotomy for pyelocaliceal lithiasis) who was admitted to our clinic in October 2007 for acute left renal colic. Investigated and diagnosed with left distal ureteral stone and right inferior caliceal lithiasis, the patient was submitted to left retrograde ureteroscopy with contact lithotripsy (Swiss Lithoclast) of the stone followed by the insertion of a double J ureteral stent – due to significant lesions caused by the stone as well as fragmentation of the stone.

Subsequently the patient returned after four weeks in order to withdraw the left ureteral stent and continue with the treatment for the right caliceal lithiasis. A surprise in the imaging re-evaluation (ultrasonography plus radiography) showed intense calcification of both extremities (proximal and distal) of the ureteral stent (Fig. 1).

An attempt to extract the stent could have been extremely risky and doomed to fail so we decided to perform extracorporeal shockwave lithotripsy for the proximal stent encrustations. We performed a session of ESWL involving 3,000 shock waves. Subsequent radiology revealed the decrustation of the pyelic end of the stent (Fig. 2).

After ESWL, the ureteral stent was easily pulled out by cystoscopy and its simple examination showed the success of ESWL among the proximal encrustations of the stent as well as the presence of the distal calcifications, which were left in place intentionally in order to be examined to establish the possible composition of future stones.

The fragments detached from the proximal end of the stent remained in the pelvis and inferior calyx after extracting the double J ureteral stent and were treated using another session of ESWL. The ultrasonography and plain abdominal radiography performed three weeks after this second session of ESWL identified only a small residual lithiasic fragment (<4 mm) in the left inferior calyx.

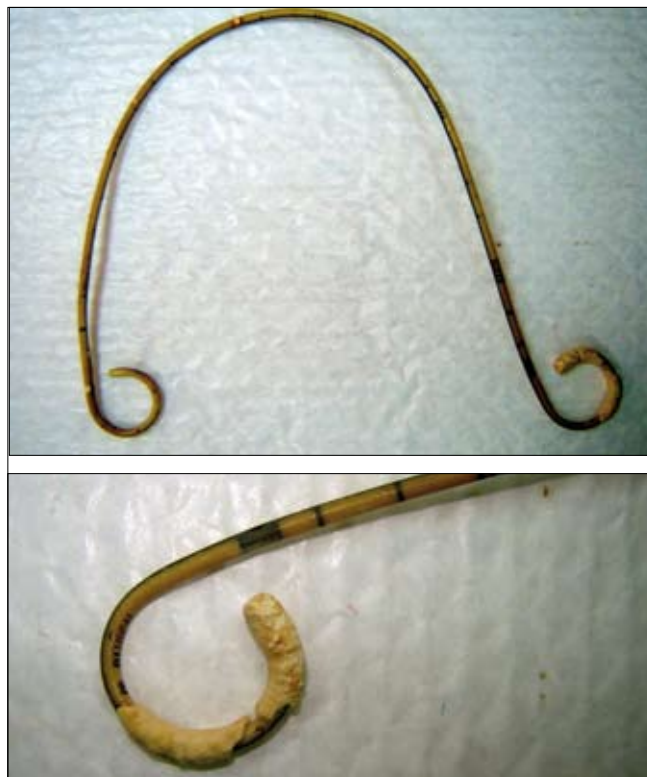

Fig. 3. Ureteral double J stent post-ESWL extracted by cystoscopy.

DISCUSSION

In daily urological practice the use of double J ureteral stents is very frequent. Either used as internal urinary drainage for emergencies (ex. subintractant or feverish renal colic) or in post-procedural ureteral stenting (ex. post-ureteroscopy), the double J ureteral stents may calcify. Calcification may occur during the well-known period of stent utilization (approx. three months) due to a poor urine composition in the patient or, more frequently, by neglecting the scheduled time for exchange or extraction of the stent (for the record, we had a patient who returned six years after the insertion of an double J ureteral stent, having ignored the urologist's recommendation) [7].

Ureteral stent placement is a common procedure in daily urologic practice. Management of problems associated with overdue removal of encrusted stents requires multimodal stone therapy. We can utilize various types of lithotripsy for the encrustations and stent extraction, including ESWL and cystoscopic extraction as well as the percutaneous approach with nephroscopic extraction after preliminary release of the distal end of the stent. It is imperative not to use force while drawing out the stent. Efforts to extract the stent can lead to ureteral avulsion or other iatrogenic lesions, which may compromise renal function or result in intracorporeal stent breakage [5].

ESWL is a less invasive method of treatment in the management of urinary lithiasis; a valid rule also for encrusted ureteral stents. The shock waves can be directed at the proximal or ureteral part of the encrusted stent while guided by ultrasonography or fluoroscopy [8].

The encrustations are useful for the patient and urologist. Evaluation of the crystalline composition of the encrustations on double J ureteral stents forms the basis of urolithiasis prophylaxis. Mid-infrared spectroscopy analysis of stent encrustations is a reliable method of predicting stone composition when the stone cannot be retrieved. Systematic mid-infrared spectroscopy analysis of

stent encrustations is not recommended, but can be very useful in clinical situations when no stone is available [4]. Biochemical and optical analyses of encrustations mainly revealed calcium oxalate, calcium phosphate, and ammonium magnesium phosphate. Calcium oxalate was the main crystalline phase, especially in the absence of urinary infection, representing the principal component of double J ureteral stent encrustations [7]. Thus, encrustation prophylaxis may consist of preventive measures usually applied in cases of recurrent idiopathic calcium oxalate urolithiasis.

The peculiarity of this case is represented by the short indwelling time (six weeks), allowing for the stent encrustation relative to the higher rate of stone recurrence observed in this patient. Urine and blood analysis did not reveal any metabolic abnormality.

CONCLUSIONS

Successful management of encrusted ureteral stents requires careful planning and may entail a combination of endourologic approaches. It is imperative to avoid using significant force, which can result in severe ureteral injury or breakage of the stent. Imaging plays a pivotal role in determining the appropriate surgical management of the encrusted and retained stent. Combined endourologic techniques can achieve safe removal of encrusted stents if treatment is tailored to the volume of encrustation and associated stone. Imaging evaluation and documentation of negative urine culture are imperative prior to any attempt to remove the stent. We believe in treating the distal component prior to managing any proximal or ureteral components and extracorporeal shockwave lithotripsy is the first line of treatment.

The combination of potentially significant morbidity associated with neglected internal stents as well as the increased mobility of our society and our patients has provided the impetus for the pursuit of novel methods to limit such complications. It is important that the treating urologist clearly communicates to the patient the presence of any internal urologic stents, the temporary intent of their use, the risks with prolonged indwelling times, and the need for appropriate follow-up.

The ideal ureteral stent biomaterial has yet to be discovered and an area of promising development is the drug eluting stent to prevent infection and encrustation. Novel stent designs incorporating antimicrobial eluting stents and stents with enzymes to degrade urinary oxalate have shown promise *in vitro* to minimize stent morbidity [8, 9].

REFERENCE

1. Aravantinos E, Gravas S, Karatzas AD et al: *Forgotten, encrusted ureteral stents: a challenging problem with an endourologic solution*. J Endourol 2006; 20 (12): 1045-1049.
2. Singh I, Gupta NP, Hemal AK et al: *Severely encrusted polyurethane ureteral stents: management and analysis of potential risk factors*. Urology 2001; 58 (4): 526-531.
3. Bukkapatnam R, Seigne, Helal MJ et al: *1-step removal of encrusted retained ureteral stents*. J Urol 2003; 170 (4 Pt 1): 1111-1114.
4. Roupret M, Daudon M, Hupertan V et al: *Can ureteral stent encrustation analysis predict urinary stone composition?* Urology 2005; 66 (2): 246-251.
5. Di Grazia E, La Rosa P, Amuso G: *One step endourologic management of severely encrusted stent in solitary kidney with renal impairment. A case report*. Minerva Urol Nefrol 2006; 58 (3): 169-171.
6. Rana AM, Sabooh A: *Management strategies and results for severely encrusted retained ureteral stents*. J Endourol 2007; 21 (6): 628-632.
7. Bouzidi H, Traxer O, Doré B et al: *Characteristics of encrustation of ureteric stents in patients with urinary stones*. Prog Urol 2008; 18 (4): 230-237. Epub 2008 Apr 10.
8. Vanderbrink BA, Rastinehad AR, Ost MC, Smith AD: *Encrusted urinary stents: evaluation and endourologic management*. J Endourol 2008; 22 (5): 905-912.
9. Haleblan G, Kijvikai K, de la Rosette J et al: *Ureteral stenting and urinary stone management: a systematic review*. J Urol 2008; 179 (2): 424-430.
10. Borboroglu PG, Kane CJ: *Current management of severely encrusted ureteral stents with a large associated stone burden*. J Urol 2000; 164: 648.
11. Bultitude MF, Tiptaft RC, Glass JM, Dasgupta P: *Management of encrusted ureteral stents impacted in upper tract*. Urology 2003; 62: 622.

Correspondence

Catalin Ciuta
50, Bldg. Carol I
700503, Iasi, Romania
phone +40 740 190694
cataciuta@yahoo.com