

An unusual foreign body in urethra: nail clippers

Namik Hatipoglu¹, Mehmet Yucel², Nebahat Hatipoglu³, Serhat Yentur⁴, Attila Semercioz⁴

¹S.B. Diyarbakir Educational Hospital, Department of Urology, Diyarbakir, Turkey

²Dumlupinar University Faculty of Medicine, Department of Urology Kutahya, Turkey

³S.B. Diyarbakir Educational Hospital, Department of Radiology, Diyarbakir, Turkey

⁴S.B. Bagcilar Educational and Research Hospital, Department of Urology, Istanbul, Turkey

KEY WORDS

nail scissors ▶ urethra ▶ foreign body

ABSTRACT

A 37-year-old mentally retarded male patient complained of voiding difficulties. Physical examination revealed a foreign body in the urethra. The foreign body was found to be nail clippers and was removed with open surgery. This case of self-inserted nail clippers in the urethra by the patient is the first published report to our knowledge.

INTRODUCTION

The variety of self-inserted intraurethral foreign bodies have been reported in literature [1]. Most foreign bodies were associated with autoerotic stimulation, psychiatric disorders, intoxication, iatrogenicity, or migration from neighboring organs or tissues [2]. These patients presented with dysuria, hematuria, urinary retention, penile pain, and/or swelling [3]. We report a mentally retarded patient who inserted nail clippers into his urethra. He then complained of a voiding problem. Our patient is the first case, to our knowledge, with self-inserted intraurethral nail clippers.

CASE REPORT

A 37-year-old male patient was admitted to our clinic with complaints of difficulty in voiding. The patient was mentally retarded. He had self-inserted nail clippers into his urethra four days earlier. He was receiving psychiatric treatment. Urological

examination of the glans penis and penile skin was forced. The proximal penile urethra was swollen due to the intraurethral foreign body. The base of the penis was firm and a painful mass with smooth borders was detected upon palpation. Approximately 5 x 1 cm in size with smooth contours, the nail clippers with sharp distal tip, was detected in the proximal penile urethra in pelvic X-ray (Fig. 1).

The intraurethral foreign body was extracted during open surgery under general anesthesia. A circumflex incision and degloving were performed under the preputial line. The urethral foreign body was removed with minimal damage, an incision approximately 1cm long in the medial line of the corpus spongiosum (Figs. 2, 3, 4). An 18F silicone catheter was inserted intraurethrally and the urethra was repaired with 4/0 vicryl. The skin was repaired with 4/0 rapid vicryl. The penis was covered with a compression bandage and the operation was concluded. There were no complications in the post-operative period. The patient was discharged with follow-up in the psychiatric clinic. The urethral catheter was removed 15-days post-operatively and first and third month follow-up revealed normal voiding.

DISCUSSION

Self-inserted intraurethral foreign bodies have been reported in psychiatric patients. These patients usually introduce foreign bodies into the urethra during masturbation [4, 5]. Literature has reported a variety of foreign bodies; such as pencils, electric cables, thermometers, glass rods, toothbrushes, candles, serum sets, balloons, hairpins, wires, ampules, broken keys, plastic spoon handles, and pocket batteries [6, 7]. These foreign bodies can cause lower abdominal pain, dysuria, urethral discomfort, pollakiuria, nocturia, hematuria, gross bleeding from the urethra, painful erection, difficulty in voiding, and urinary retention [7, 8]. Delayed treatment can cause chronic conditions, such as repeated infections, urinary retention, squamous cell carcinoma, urethral stenosis, rectal abscess, urethral rip secondary to periurethral abscess and/or fistula, calcification of foreign bodies, and stone formation [5, 8, 9].

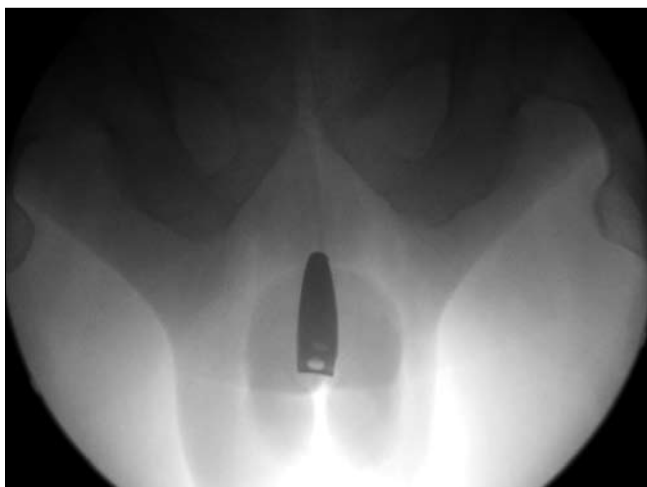


Fig. 1. X-ray showing urethral foreign body (nail clippers).

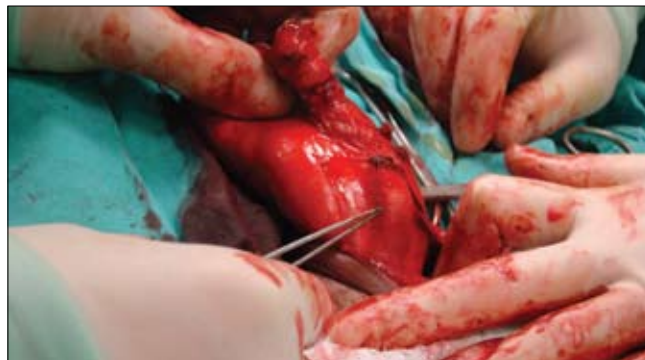

Fig. 2. Location of urethral foreign body during surgery.

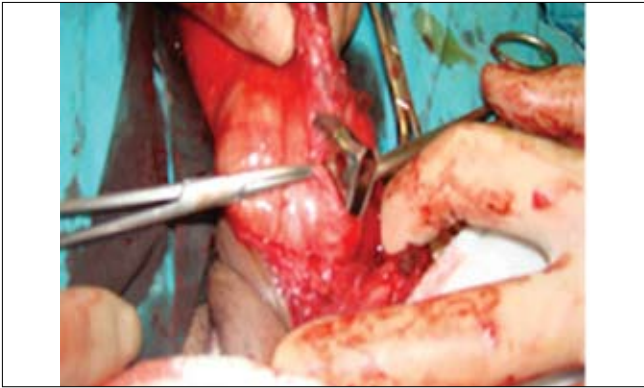

Fig. 3. Intraurethral foreign body (nail clippers).

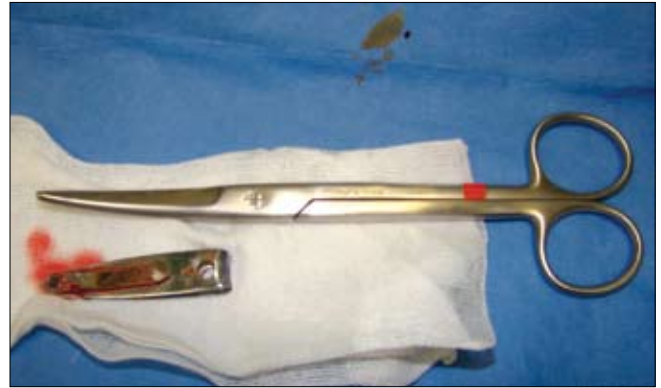

Fig. 4. Foreign body (nail clippers) after removal.

Optimal treatment depends on patient type, degree of urethral deformation, and shape of the foreign body. Correct treatment results in foreign body removal, most commonly by the endoscopic method, but sometimes requiring open surgery.

Initially, a good history should be taken and detection and investigation of a possible foreign body should be done by x-ray or ultrasonography or rarely by CT scan [8, 9]. Various methods of foreign body removal have been described such as meatotomy, cystoscopy, internal and external urethrotomy, and suprapubic cystostomy. Endoscopic removal of foreign bodies is often considered the first treatment choice [6].

Early and immediate removal of the urethral foreign body is recommended. In order to discover underlying mental health disorders and reduce the risk of recurrence it is suggested that the patient be referred for psychiatric evaluation [6].

The most frequent complications of foreign bodies are urethritis, urethral tear with periurethral abscess and/or fistula, hemorrhage, and urethral diverticula [8].

Aliabadi et al. reported that reasons for foreign body self-insertion in their study of 18 patients included: autoeroticism in six (33%), obvious psychiatric causes in two (11%), for assistance of voiding in seven (39%), and in three patients (17%) no definite reason could be determined [10].

Medical treatment of symptoms is always inadequate in these patients. Psychiatric treatment is a more important factor than foreign body removal. To avoid repeated attempts for intraurethral self-insertion, a psychiatric evaluation should be performed.

Rahman et al. reported that, among 17 patients with intraurethral foreign body, plain radiographs were sufficient in 14 patients and ultrasonography and CT scan was required in three [1]. They concluded that radiological evaluation is necessary to determine the exact size, location, and number of foreign bodies.

Van Ophoven et al. reviewed the literature and concluded that the most common cause of foreign body insertion is sexual or erotic in nature [11]. They suggested that, when possible, endoscopic or minimally invasive techniques of removal should be performed. In case of associated severe inflammation, surgical retrieval may be required.

In our case, the urethral foreign body was confirmed with the help of x-ray. We successfully removed the urethral foreign body with open surgery.

CONCLUSION

A self-inserted foreign body in the urethra is a rare situation. First line treatment must be endoscopic manipulation, but sometimes open-procedures may be necessary.

REFERENCES

1. Rahman NU, Elliott SP, McAninch JW: *Self-inflicted male urethral foreign body insertion: endoscopic management and complications*. BJU Int 2004; 94 (7): 1051-1053.
2. Stravodimos KG, Koritsiadis G, Koutalellis G: *Electrical wire as a foreign body in a male urethra: a case report*. J Med Case Reports 2009; 3: 49.
3. Sukkarieh T, Smaldone M, Shah B: *Multiple foreign bodies in the anterior and posterior urethra*. Int Braz J Urol 2004; 30 (3): 219-220.
4. Walsh P, Moustafa M: *Retention of urethrovessical foreign bodies: case report and literature review*. J Emerg Med 2000; 19 (3): 241-243.
5. Granados EA, Riley G, Rios GJ et al: *Self introduction of urethrovessical foreign bodies*. Eur Urol 1991; 19 (3): 259-261.
6. Trehan RK, Haroon A, Memon S et al: *Successful removal of a telephone cable, a foreign body through the urethra into the bladder: a case report*. J Med Case Reports 2007; 27; 1: 153.
7. Ayyildiz A, Gürdal M, Nuhoglu B et al: *A foreign body self-inserted via the urethra into the bladder: pocket battery*. Int Urol Nephrol 2003; 35 (2): 251-252.
8. Ali Khan S, Kaiser CW, Dailey B et al: *Unusual foreign body in the urethra*. Urol Int 1984; 39 (3): 184-186.
9. Costa G, Di Tonno F, Capodiceci S et al: *Self-introduction of foreign bodies into the urethra: a multidisciplinary problem*. Int Urol Nephrol 1993; 25 (1): 77-81.
10. Aliabadi H, Cass AS, Gleich P et al: *Self-inflicted foreign bodies involving lower urinary tract and male genitals*. Urology 1985; 26 (1): 12-16.
11. van Ophoven A, deKernion JB: *Clinical management of foreign bodies of the genitourinary tract*. J Urol 2000; 164 (2): 274-87.

Correspondence

Mehmet Yucel
 Dumlupinar University Faculty of Medicine
 Department of Urology
 43270 Kutahya, Turkey
 phone: +90 274 265 2031
 myucel75@gmail.com