

# Evaluation of Jordan's meatoplasty for the treatment of fossa navicularis strictures. A retrospective study

Prakash Babu, Arvind Nayak, Tarun Dilip Javali, Prarthan Joshi, Horahally Krishnareddy Nagaraj, Kuldeep Aggarwal

MS Ramaiah Medical College, Bangalore, India

**Citation:** Babu P, Nayak A, Javali TD, Joshi P, Nagaraj HK, Aggarwal K. Evaluation of Jordan's meatoplasty for the treatment of fossa navicularis strictures. A retrospective study. Cent European J Urol. 2017; 70: 103-106.

## Article history

Submitted: Sept. 22, 2016  
Accepted: Dec. 5, 2016  
Published online: Jan. 18, 2017

## Corresponding author

Arvind Nayak  
MS Ramaiah Medical  
College  
25-A/47 8th main RMV  
Extension Sadashivanagar  
560080 Bangalore, India  
phone: +91 998 678 3397  
arvindnayakk@gmail.com

**Introduction** Fossa navicular strictures can be a challenging problem for reconstructive urologists in which there is a need to achieve good cosmetic results along with a consistent stream. Our aim was to retrospectively evaluate the outcome of Jordan meatoplasty in the management of fossa navicularis strictures.

**Material and methods** A total of 25 patients who underwent Jordan meatoplasty for the management of fossa navicularis strictures between 2011 and 2016 were retrospectively reviewed. All patients were evaluated with uroflometry. Preoperative retrograde urethrogram was performed in all patients to exclude proximal urethral strictures. The operative details including operative time were analyzed. All patients were evaluated for urinary pattern changes, irritative voiding symptoms and with uroflometry at the end of three months. Hypospadias objective score evaluation (HOSE) was applied at the end of three months for the evaluation of cosmetic outcome.

**Results** The mean age of patients was 64 years and the mean operative time was 42 minutes. The mean follow up period was 30 months. The mean post-operative peak urine flow rate at three months after removal of the catheter was 18 ml per second. The meatus was slit shaped in 84%. Only 12% of patients complained of splay of urine at the end of three months. 96% of patients were stricture free, with one patient developing a recurrence at 12 months of follow up which was managed by urethral dilatation.

**Conclusions** Jordan meatoplasty is a feasible and easily reproducible technique for the management of distal penile strictures.

**Key Words:** fossa navicularis stricture <> meatoplasty <> distal penile stricture

## INTRODUCTION

Fossa navicular strictures can be a challenging problem for reconstructive urologists. It can be secondary to instrumentation, catheterization, congenital, lichen sclerosis or idiopathic. The challenge for the urologist lies in the need to achieve cosmetic results along with a consistent stream of urine without much splaying. Management options include dilatation, meatotomy and several flap and graft meatoplasties. Meatoplasty procedures can lead to splaying of urine with a deformed stream. The aim of this study was to retrospectively evaluate the outcome of Jordan me-

atoplasty in the management of fossa navicularis strictures

## MATERIAL AND METHODS

Between 2011 and 2016, 25 patients with fossa navicularis strictures were managed with Jordan's meatoplasty. The age of patients ranged from 28–72 years, with a mean age of 64 years. In ten (40%) patients the cause of the stricture was prior instrumentation in the form of Transurethral resection of prostate (TURP), catheterisation was the cause in four (16%) patients and aetiology could not be established in 11 (44%) patients. Patients

with evidence of balanitis xerotica obliterans (BXO) were excluded.

All patients were evaluated with uroflometry and the mean peak flow rate was 7 ml per second (range 4.2–11). A preoperative retrograde urethrogram was performed in all patients to exclude proximal urethral strictures.

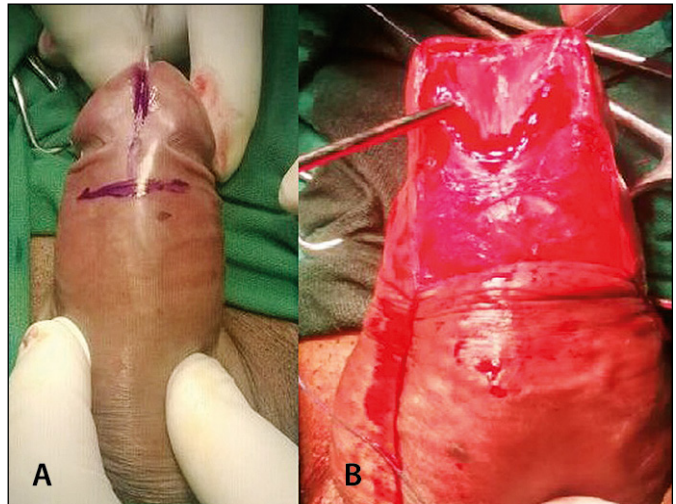
The surgery was performed with regional anaesthesia after providing antibiotic prophylaxis. An initial vertically ventral incision on the glans and a short sub coronal circumcision incision were used (Figure 1A). The skin along with the dartos was then elevated to expose the fossa navicularis. A ventral stricturotomy was done extending 10–15 millimetres into the normal urethra (Figure 1B). A transverse island flap of the ventral part of the foreskin was elevated along with the fasciocutaneous dartos pedicle; the length and width of which was equal to the meatal defect, such that the dimension of the neofossa was 30 French (Figure 2A). The remaining fore skin was excised. The glans wings were then elevated to cover the flap without tension and provide normal configuration of the glans. The flap was then rotated and inverted into the meatal defect so that the epithelium faced the lumen (Figure 2B). The flap was sutured in a continuous fashion with a 5-0 vicryl suture over a 16 French Foley catheter. Lastly, the glandular wings were sutured in two layers over the flap in an interrupted fashion with 5-0 vicryl (Figure 3).

The catheter was removed at the end of two weeks and urinary pattern was noted. All patients were evaluated for urinary pattern changes, irritative voiding symptoms and with uroflometry at the end of three months. Hypospadias objective score evaluation (HOSE) was applied at the end of three months for the evaluation of the cosmetic outcome. A successful outcome was defined as a subjective and objective improvement in urinary flow without the need for further instrumentation (dilatation) during follow-up.

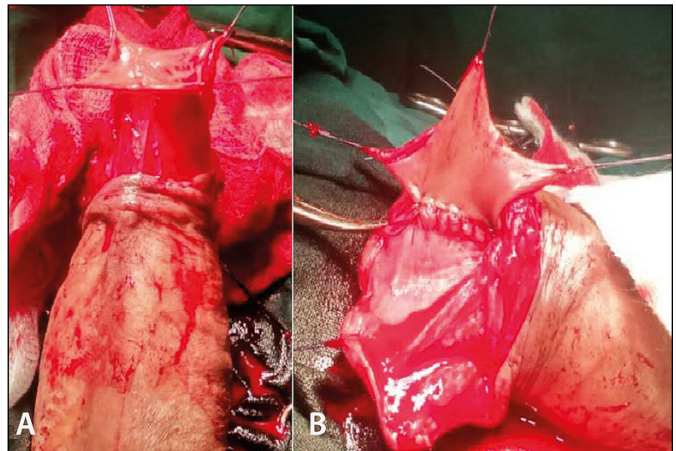
## RESULTS

It was found that the mean operative time was 42 minutes. The follow up period ranged from 6 to 54 months with a mean of 30 months. The mean post-operative peak urine flow rate at three months following removal of catheter was 18 ml per second (range 14–30 ml per second).

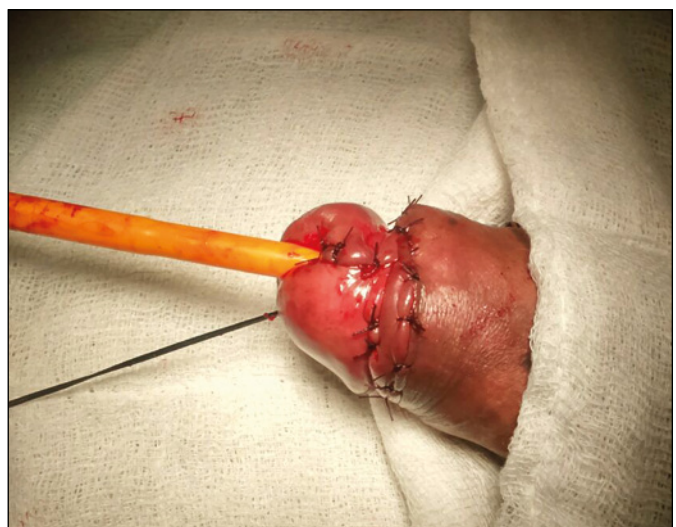The HOSE score was applied at the end of three months to assess cosmetic results (Table 1). All the patients had a HOSE score of  $\geq 14$ , indicating excellent cosmetic and functional results. In all patients the meatus was noted at the tip of the glans.



**Figure 1A.** Showing a vertically ventral incision on the glans and a short sub coronal circumcision incision. **B.** Ventral meatotomy.



**Figure 2A.** Mobilised transverse island ventral preputial flap. **B.** Flap sutured such that the epithelium faces the lumen.



**Figure 3.** Glanuloplasty.

The meatus was slit shaped in 84% and only 12% of the patients complained of splay of urine at the end of three months. None of the patients developed fistula during the follow up period.

Superficial flap necrosis was found in one patient, which was conservatively managed. Only one patient developed a recurrence at 12 months of follow up and was managed with urethral dilatation and 96% of the patients were stricture free.

## Review of literature

Distal urethral strictures confined to the fossa navicularis account for nearly 18% of all anterior urethral strictures [1]. These strictures can result from trauma, instrumentation, prior hypospadias surgery [2, 3], and lichen sclerosis; which is the most common aetiology accounting for 12–42% of cases [3, 4]. Trauma following instrumentation is another leading cause of fossa navicularis strictures. Despite advances in endoscopic instruments, the incidence of iatrogenic distal urethral strictures ranges from 6.3–31% [4, 5, 6]. Prolonged instrumentation can cause urethral strictures by compression and ischemia at fixed and narrow regions of the urethra. Idiopathic strictures are usually more common in the younger population and might be either congenital or delayed manifestations of unrecognized childhood trauma [7]. In our series, the majority (44%) were idiopathic, 40% were caused secondary to instrumentation and 16% were due to catheterization.

Management of distal penile strictures depends on the length of the stricture, the extent of spongiofibrosis, the quality of preputial and distal penile skin and the presence or absence of lichen sclerosis [8]. Retrograde and micturating cystourethrogram can be used to evaluate the location and length of the urethral stricture. The extent of spongiofibrosis can be evaluated with the help of ultrasonography or contrast spongiography.

Management options include urethral dilatation, visual internal urethrotomy, meatotomy and reconstructive procedures. Long term results of urethral dilatation for fossa navicularis strictures are questionable where dilatation may exacerbate the inflammatory process. Visual internal urethrotomy (VIU) can be performed in selected cases with minimal spongiofibrosis; however, a poor fulcrum and lack of leverage makes VIU technically challenging [5]. Cutting into the glans can cause significant bleeding and erectile dysfunction [5]. A ventral meatotomy can be performed to treat fossa navicularis strictures, although, it may cause significant splaying of urine and formation of a hypospadiac meatus which may lead to cosmetic deformity [9].

**Table 1.** Evaluation of cosmetic outcome with HOSE score

HOSE variable	HOSE score	Number of patients (%)
Meatal location		
Tip of glans	4	25 (100)
Proximal Glans	3	0 (0)
Coronal	2	0 (0)
Shaft	1	0(0)
Meatal shape		
Vertical slit	2	21 (84%)
Circular	1	4 (16%)
Urinary stream		
Single stream	2	22 (88%)
Spray	1	3 (12%)
Erection		
Straight	4	25 (100)
Mild angulation	3	0 (0)
Moderate angulation	2	0 (0)
Severe angulation	1	0 (0)
Fistula		
None	4	25 (100)
Single proximal	3	0 (0)
Single distal	2	0 (0)
Multiple	1	0 (0)

Reconstructive procedures for fossa navicularis strictures involves tissue transfer with grafts and flaps. *Devine* first described the patch graft urethroplasty where a full thickness penile skin graft was used to ‘re-pave’ the fossa navicularis [5]. Extragenital tissue, such as buccal mucosa, is preferred for reconstruction of penile and fossa navicularis strictures in patients with lichen sclerosis. Posterior Auricular skin has been used in the management of penile strictures, while the same has not yet been tried for the treatment of fossa navicular strictures.

Jordan revolutionised distal meatoplasty in 1987 by describing the ventral transverse preputial island flap meatoplasty [10]. This versatile flap is based on a broad based pedicle with dartos fascia which receives its blood supply and drainage from superficial penile arteries and veins. The advantages of this flap are the laxity of penile skin, dependable blood supply and absence of hair follicles [11]. Virasoro et al. achieved a stricture free rate of 83% in 35 patients over a mean follow up period of 10.2 years [6]. All of the failures in this study were noted in patients with lichen sclerosis. Fiala et al. reported a 100% success rate at 35 months follow up in 21 cases [11]. In our series, 96% of the patients were stricture free with a mean follow up period of 30 months. Armenakas et al. described a modification where the glans was preserved and elevated off of the urethra so that the flap could be tunnelled beneath the glans (Glans cap meatoplasty). He reported a success rate of 94% in 18 patients with a follow up of 43 months [13].

The cosmetic outcome of distal penile strictures and distal penile hypospadias is similar, hence the Hypospadias objective score evaluation (HOSE) was applied for the evaluation of cosmetic outcome in our series [14]. All of the patients in our series had the meatus opening at the tip of the glans. A slit shaped meatus was noted in 84% of the patients. The majority of the patients (88%) had a single stream of urine. None of the patients developed fistula during our follow up period.

## CONCLUSIONS

Jordan meatoplasty is a feasible and easily reproducible technique for the management of distal penile strictures. Excellent cosmetic results and improvement in urinary flow pattern can be achieved by this technique with minimal complication rates.

## CONFLICTS OF INTEREST

The authors declare no conflicts of interest.

## References

1. Santucci RA, Joyce GF, Wise M. Male urethral stricture disease. *J Urol.* 2007; 177: 1667-1674.
2. Palminteri E, Berdondini E, Verze P, De Nunzio C, Vitarelli A, Carmignani L. Contemporary urethral stricture characteristics in the developed world. *Urology.* 2013; 81: 191-196.
3. Stein DM, Thum DJ, Barbagli G, et al. A geographic analysis of male urethral stricture aetiology and location. *BJU Int.* 2013; 112: 830-834.
4. Meeks JJ, Barbagli G, Mehdiratta N, Granieri MA, Gonzalez CM. Distal urethroplasty for isolated fossa navicularis and meatal strictures. *BJU Int.* 2012; 109: 616-619.
5. Tonkin JB, Jordan GH. Management of distal anterior urethral strictures. *Nat Rev Urol.* 2009; 6: 533-538.
6. Virasoro R, Eltahawy EA, Jordan GH. Long-term follow-up for reconstruction of strictures of the fossa navicularis with a single technique. *BJU Int.* 2007; 100: 1143-114.
7. Andrich DE, Mundy AR. What is the Best Technique for Urethroplasty? *Eur Urol.* 2008; 54: 1031-1041.
8. Singh SK, Agrawal SK, Mavuduru RS. Management of the stricture of fossa navicularis and pendulous urethral strictures. *Indian J Urol.* 2011; 27: 371-377.
9. Morey AF, Lin HC, DeRosa CA, Griffith BC. Fossa navicularis reconstruction: impact of stricture length on outcomes and assessment of extended meatotomy (first stage Johanson) maneuver. *J Urol.* 2007; 177: 184-197.
10. Jordan GH. Reconstruction of the fossa navicularis. *J Urol.* 1987; 138: 102-104.
11. Onol SY, Onol FF, Onur S, Inal H, Akbaş A, Köse O. Reconstruction of strictures of the fossa navicularis and meatus with transverse island fasciocutaneous penile flap. *J Urol.* 2008; 179: 1437-1440.
12. Fiala R, Vrtal R, Zenisek J, Grimes S. Ventral prepuce flap meatoplasty in the treatment of distal urethral male strictures. *Eur Urol.* 2003; 43: 686-688.
13. Armenakas NA, Morey AF, McAninch JW. Reconstruction of resistant strictures of the fossa navicularis and meatus. *J Urol.* 1998; 160: 359-363.
14. Holland AJ, Smith GH, Ross FI, Cass DT. HOSE: an objective scoring system for evaluating the results of hypospadias surgery. *BJU Int.* 2001; 88: 255-258. ■