

## Intermittent hyperammonemic encephalopathy after ureterosigmoidostomy: spontaneous onset in the absence of hepatic failure

Wolfgang Jäger<sup>1</sup>, Anne-Odette Viertmann<sup>2</sup>, Claudia Janßen<sup>1</sup>, Frank Birklein<sup>2</sup>, Joachim W. Thüroff<sup>1</sup>, Raimund Stein<sup>1</sup>

<sup>1</sup>Department of Urology, Johannes Gutenberg University, Mainz, Germany

<sup>2</sup>Department of Neurology, Johannes Gutenberg University, Mainz, Germany

**Citation:** Jäger W, Viertmann A-O, Janßen C, Birklein F, Thüroff J, Raimund R. Intermittent hyperammonemic encephalopathy after ureterosigmoidostomy: spontaneous onset in the absence of hepatic failure. Cent European J Urol. 2015; 68: 121-124.

### Article history

Submitted: Aug. 27, 2014

Accepted: Nov. 23, 2014

Published on-line:

March 13, 2015

### Corresponding author

Wolfgang Jäger

Department of Urology

University Medical Center

Langenbeckstraße 1

55131 Mainz, Germany

phone: +49 6131 170

wolf.jaeger@gmx.de

Intermittent hyperammonemic encephalopathy after ureterosigmoidostomy is a rare, but if unrecognized, potentially lethal condition. Ureterosigmoidostomy was performed in a male patient with bladder extrophy. After 35 years, he developed hyperammonemic encephalopathy. Diagnostic procedures did not reveal hepatic nor metabolic disorders. Despite administration of preventive medical treatment, several episodes recurred. A durable prevention was finally achieved by conversion into an ileal conduit.

Intermittent hyperammonemic encephalopathy can occur decades after ureterosigmoidostomy. In the case of absence of metabolic disorders and resistance to medical treatment, conversion into a urinary diversion using an ileal segment constitutes an effective *ultima ratio*.

**Key Words:** bladder extrophy ◊ urinary diversion ◊ ureterosigmoidostomy ◊ complications  
◊ hyperammonemic encephalopathy

## CASE REPORT

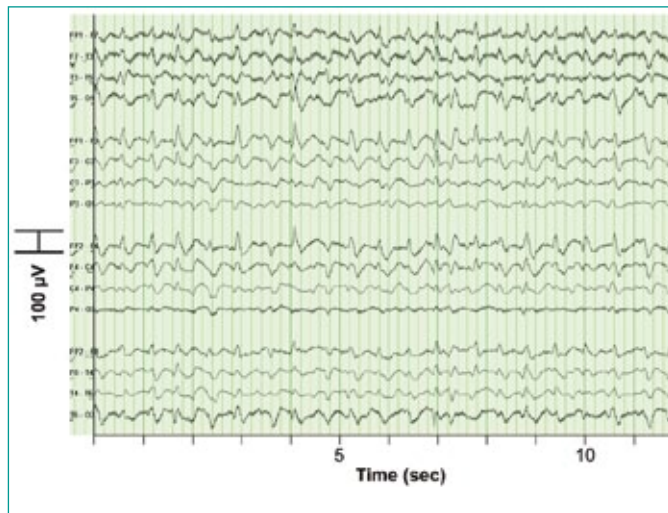
Primary ureterosigmoidostomy for bladder extrophy was performed in a 23 year old male patient. Osteoporosis developed two decades later and was treated successfully with bisphosphonates. Periodically, asymptomatic subclinical acidosis was treated with oral sodium/potassium citrate and bicarbonate. Otherwise, laboratory and clinical examinations during continuous follow-ups at our department were unremarkable.

However, 35 years after urinary diversion, the patient experienced recurrent episodes of disorientation, altered consciousness and epileptic seizures which led to repeated hospital admissions. Extended

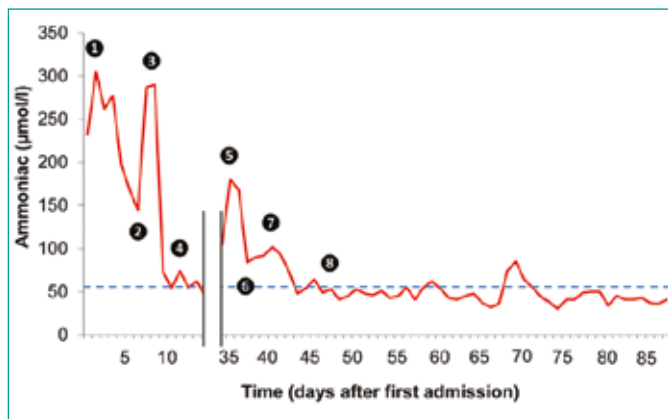
interdisciplinary examinations detected only a protein S deficiency. Subsequently, the patient received phenprocoumon for anticoagulation and prophylaxis of thromboembolic events.

Ten months later, he was again referred to the emergency department of our medical centre for severe deterioration of his mental status. The electroencephalogram (EEG) examination showed triphasic waves reflecting a non-convulsive *status epilepticus* (Figure 1), which was successfully treated by intravenous administration of phenytoin. The patient additionally received valproic acid (1600 mg daily) for long-term medication. Extended laboratory examinations were subsequently performed and revealed a hyperammonemic hyperchloremic metabolic acido-

sis (max. ammonia  $305 \mu\text{mol/l}$ , chloride  $125 \text{mmol/l}$ ; Figure 2). Despite undergoing various diagnostic procedures, neither pre-existing acute or chronic



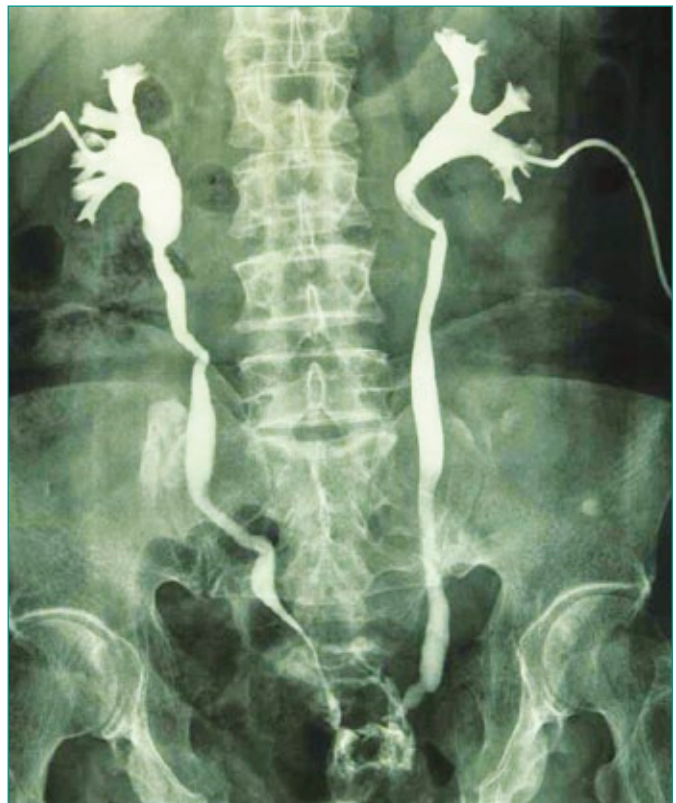**Figure 1.** Electroencephalogram (EEG). Triphasic waves indicate an acute non-convulsive status epilepticus triggered by hyperammonemic encephalopathy.



**Figure 2.** Serum levels of ammonia over time. Ammonia serum level high above upper reference point at the first admission to the emergency department [1]. Administration of lactulose, paromomycin and L-carnithin only temporarily induces a significant decrease [2, 3]. After modification of the antiepileptic treatment (replacement of valproic acid by levetiracetam), ammonia levels declined to normal values in concordance with clinical symptoms [4]. Three weeks later, a recurrent episode of elevated ammonia serum levels with clinical symptoms under ongoing medical treatment [5]. Decrease of the elevated serum level 48 hours after bilateral insertion of percutaneous nephrostomies [6]. De novo increase of ammonia with neurological symptoms after clamp of nephrostomies [7]. Normal serum levels of ammonia over long-term follow-up [8]. The upper reference point of serum ammonia ( $<55 \mu\text{mol/l}$ ) indicated by the dashed line.

liver failures nor congenital or acquired metabolic disorders were detected. Ultrasonic examination of the urinary tract excluded hydronephrosis or sigmoid distension. Treatment of the hyperammonemic hyperchloridemia with lactulose, paromomycin and L-carnitine decreased the ammonia serum level only temporarily. After replacing valproic acid with levetiracetam ( $3000 \text{mg}$  daily) for antiepileptic treatment, the ammonia levels declined to standard values (Figure 2).

Despite ongoing antiepileptic medication, another *status epilepticus* occurred three weeks later, again related to hyperammonia. In default of other possible etiologies, a bacterial ureolysis in the bowel was considered although the urinary tract and sigmoid colon did not show any signs of restricted urinary drainage. To verify this hypothesis, bilateral percutaneous nephrostomies were inserted (Figure 3) and 48 hours later, the elevated serum levels of ammonia and chloride indeed decreased to the normal range. The psychomotor symptoms (drowsiness, disorientation) normalized in concordance with the laboratory findings. Tentative clamping of nephrostomies resulted in the recurrence of hyperammonemia and psychomotor symptoms.



**Figure 3.** Antegrade pyelography. Contrast study after insertion of nephrostomies testifies absence of impaired upper tract drainage and retention of urine in the sigmoid colon.

Subsequently, the patient agreed to a conversion of the ureterosigmoidostomy into an ileal conduit, despite being previously satisfied with the ureterosigmoidostomy. With the exception of a postoperative subsegmental pulmonary embolism (pre-existing protein S deficiency), the patient did not suffer from further complications. Continuous clinical and laboratory monitoring was performed postoperatively and indicated normal serum levels of ammonia, as well as normal hepatic and renal function. Over the 31 months since the procedure, the patient has not presented with any further episodes of hyperammonemia, epileptic seizures or encephalopathic symptoms. Antiepileptic medication was stopped.

## DISCUSSION

Ureterosigmoidostomy was first performed by John Simon in 1851 for a patient presenting with bladder extrophy [1]. This form of continent urinary diversion and its modification – the sigma-rectum pouch – are still options for primary or secondary urinary diversion in patients who are not eligible for primary bladder reconstruction [2, 3, 4].

Episodes of hyperammonemic encephalopathy after ureterosigmoidostomy are extremely rare, with only a few cases reported [5-14]. This severe neurological disorder is caused by elevated serum levels of ammonia in the post-hepatic blood circulation. After passage of the blood brain barrier, ammonia accumulates in the astrocytes where it disturbs neuronal function. The accompanying symptoms consist of somnolence, seizures and behavioral alterations [15]. In the worst case scenario, hyperammonemia can be lethal [15]. In ureterosigmoidostomy, elevated serum levels of ammonia in the portal vein can be caused by the exposure of the colon to urine [16]. Specific bacterial colonization in the colon (e.g. *Proteus mirabilis*) may cause fermentation of uric acid to ammonia and subsequent spill over into the blood stream. However, a reduced metabolic capacity of the liver (due to acute or chronic diseases) or portocaval shunts are generally required for pathological serum levels of ammonia in post-hepatic circulation [17]. As in the presented case, treatment with valproic acid can lower carnitine in the urea cycle and thus exacerbate hyperammonia [13] (Figure 2). Episodes of hyperammonemic encephalopathy after

ureterosigmoidostomy without the presence of concomitant hepatic or metabolic failure (deficiencies of urea-cycle enzymes) are rare [7, 9-11], with only five cases reported in literature. Two of these cases had a history of previous alcohol abuse [7, 9] and the other two suffered from congenital muscular atrophy, which may also predispose to hyperammonemia [11]. The present report is the second with hyperammonemic encephalopathy after ureterosigmoidostomy in the absence of additional pre-existing metabolic pre-disposition (hyperammonemia persisted after stopping treatment with valproic acid). During 31 months of follow-up, all relevant laboratory values (ammonia, chloride, sodium, base excess) were monitored at least bi-weekly and all remained in the normal range.

The exact reason for the long lag after urinary diversion until presentation of hyperammonemia remains unclear. The metabolic disorder was presumably triggered by bacterial overgrowth (bacteriogenic ureapoesis). However, it seems evident that the absorption of ammonia in the sigmoid exceeded the physiologic metabolic capacity of the liver despite the absence of hepatic or metabolic co-morbidities. Antiepileptic treatment with valproic acid, though initiated in order to treat a symptom of the hyperammonemic hyperchloridemia, probably additionally increased the ammonia serum level (Figure 2).

In conclusion, hyperammonemic encephalopathy after ureterosigmoidostomy is an iatrogenic problem which must be considered in the differential diagnosis of unclear mental disorders, altered consciousness and seizures. In cases of persistence and recurrence of symptoms despite medical therapy, a transient low-pressure urinary diversion which decreases bowel contact with urine should be established by bilateral insertion of nephrostomies (in our case) or by placement of a rectal tube as an emergency treatment [5]. Furthermore, a possible success of a surgical conversion into a permanently incontinent urinary diversion can be easily evaluated preoperatively. Such an irreversible surgical approach should only be performed after definitive exclusion of all other possible etiologies of hyperammonemic encephalopathy [7, 10, 11]. From both literature and our experience, this approach seems an appropriate and successful strategy in preventing further episodes of hyperammonemic encephalopathy.

## References

- Simon, J. Ectopia vesica (Absence of the anterior walls of the bladder and pubic abdominal parities); operation for directing the orifices of the ureter into the rectum; temporary success; subsequent death; autopsy. *Lancet*. 1852; 2: 568-570.
- Hautmann RE, Abol-Enein H, Davidsson T, Gudjonsson S, Hautmann SH, Holm HV, et al. ICUD-EAU International Consultation on Bladder Cancer 2012: urinary diversion. *Eur Urol*. 2013; 63: 67-80.
- Pahernik S, Beetz R, Schede J, Stein R, Thüroff JW. Rectosigmoid pouch (Mainz Pouch II) in children. *J Urol*. 2006; 175: 284-287.
- Stein R, Fisch M, Black P, Hohenfellner R. Strategies for reconstruction after unsuccessful or unsatisfactory primary treatment of patients with bladder extrophy or incontinent epispadias [see comments]. *J Urol*. 1999; 161: 1934-1941.
- Mounger EJ, Branson AD. Ammonia encephalopathy secondary to ureterosigmoidostomy: a case report. *J Urol*. 1972; 108: 411-412.
- Mortensen E, Lyng G, Juhl E, Egense J, Schwartz M. Ammonia-induced coma after ureterosigmoidostomy. *Lancet*. 1972; 1: 1024.
- Kaufman JJ. Ammoniogenic coma following ureterosigmoidostomy. *J Urol*. 1984; 131: 743-745.
- Edwards RH. Hyperammonemic encephalopathy related to ureterosigmoidostomy. *Arch Neurol*. 1984; 41: 1211-1212.
- Gilbert GJ. Acute ammonia intoxication 37 years after ureterosigmoidostomy. *South Med J*. 1988; 81: 1443-1445.
- Cascino GD, Jensen JM, Nelson LA, Schutta HS. Periodic hyperammonemic encephalopathy associated with a ureterosigmoidostomy. *Mayo Clin Proc*. 1989; 64: 653-656.
- Kaveggia FF, Thompson JS, Schafer EC, Fischer JL, Taylor RJ. Hyperammonemic encephalopathy in urinary diversion with urea-splitting urinary tract infection. *Arch Intern Med*. 1990; 150: 2389-2392.
- Donnard G, Dumotier J, Le Dantec P, Suppini A, Quinot JF. Hyperammonemia encephalopathy after ureterosigmoidostomy. *Cah Anesthesiol*. 1996; 44: 149-151.
- Schwarz S, Georgiadis D, Schwab S, Gehlen F, Mayatepek E, Zoubaa S. Fulminant progression of hyperammonaemic encephalopathy after treatment with valproate in a patient with ureterosigmoidostomy. *J Neurol Neurosurg Psychiatry*. 2002; 73: 90-91.
- Ohnishi S, Yoshida T, Makiyama H, Usui K, Kudo M, Kobayashi T, et al. Hyperammonemic encephalopathy in a patient with ureterosigmoidostomy and acute hepatitis: a specific case of fulminant hepatic failure. *Dig Dis Sci*. 2003; 48: 821-823.
- Wilkinson DJ, Smeeton NJ, Watt PW. Ammonia metabolism, the brain and fatigue; revisiting the link. *Prog Neurobiol*. 2010; 91: 200-219.
- Koch MO, McDougal WS, Thompson CO. Mechanisms of solute transport following urinary diversion through intestinal segments: an experimental study with rats. *J Urol*. 1991; 146: 1390-1394.
- Poh Z, Chang PE. A current review of the diagnostic and treatment strategies of hepatic encephalopathy. *Int J Hepatol*. 2012; doi: 10.1155/2012/480309. ■

## Index of authors

- A** Marek Adamek 102  
Alp Ozgur Akdemir 86  
Binhan Kagan Aktas 51, 60, 86  
Stefan Aufderklamm 18
- B** Marek Babjuk 15  
Huseyin Badem 91  
Mevlana Derya Balbay 18  
Umit Bayol 30  
Elham Behzadi 99  
Payam Behzadi 99  
Simone Bier 18  
Frank Birklein 121  
Mariusz Blewniewski 68  
Johannes Böttge 18  
Suheyra Uyar Bozkurt 72  
Bogdan Braticcevi 9  
Antonín Brisuda 9  
Suleyman Bulut 51, 86  
Matthew I. Bury 115
- C** Ebru Cakir 30  
Ozgun Cakmak 30  
Abdullah Erdem Canda 18  
Jessica T. Casey 61  
Victor Cauni 9  
Mucahit Cavis 91  
Sonia Chabbra 37  
Ersin Cimentepe 91
- D** Jesús Javier de la Peña Barthel 24
- Aslan Demir 72  
Rauf Taner Divrik 30  
Caroline Dong 61  
Tomasz Drewna 5, 57, 109
- E** Akif Ersoy Erkmen 51, 86
- F** Pamela Portella Fontana 24  
Natalie J. Fuller 115
- G** Georgios Gakis 18  
Cevdet Serkan Gokkaya 51, 60, 86  
Ángel Tabernero Gómez 24  
Alyssa Greiman 61  
Viacheslav Grygorenko 9
- H** Omar Halalsheh 18  
Jan Hrbáček 95
- I** Yalcin Nazmi İlker 72  
Ilkay Bekir Incebay 91
- J** Wolfgang Jäger 121  
Claudia Janßen 121  
Kajetan Juszcak 57
- K** Mehmet Karabakan 51, 86  
Omer Faruk Karatas 91  
Atif Katib 79  
Stephanie J. Kielb 61  
Ziya Kirkali 45
- Rafał Kliś 68  
Tomasz Kloskowski 109  
Ulku Kucuk 30  
Santosh Kumar 37
- L** Ramesh Lamba 37  
Jesús Cisneros Ledo 24  
Martyn-Zenovii Lesnyak 9  
Janusz Lisiński 9  
Joceline S. Liu 61
- M** Shivani Malik 37  
Michał Markowski 68  
Ali Memis 51, 86  
Johannes Mischinger 18  
Shubhra Mukherjee 61
- O** Cuneyt Ozden 51  
Esra Ozkara 45
- P** Emel Ebru Pala 30  
Wojciech Perdziński 102  
Cristian Persu 9, 17  
Marta Pokrywczyńska 109  
Sławomir Poletajew 9, 17
- R** Piotr Radziszewski 9  
Praveen Rana 37  
Reza Ranjbar 99  
Steffen Rausch 18  
Kacper Renk 9
- Juan Gómez Rivas 24  
Waldemar Różański 88
- S** Leslie Cuello Sánchez 24  
Monika Sangwan 37  
Christian Schwentner 18  
Jesús Díez Sebastián 24  
Rajeev Sen 37  
Ozlem Sezer 30  
Arun K. Sharma 115  
Allen Sim 18  
Sonia Singh 37  
Sunita Singh 37  
Raimund Stein 121  
Arnulf Stenzl 18
- T** Joachim W. Thüroff 121  
Tilman Todenhöfer 18  
Polat Türker 72  
Emre Tuzel 45
- U** Dogan Unal 91
- V** Anne-Odette Viertmann 121
- W** Linnea Wethkam 115
- Y** Sergio Alonso y Gregorio 24  
Mehmet Erol Yildirim 91  
Kutsal Yorukoglu 45