

The Endo GIA stapler in the paravaginal dissection during radical cystectomy

Endre Zoltan Neulander

Ben Gurion University, Soroka UMC, Department of Urology, Beer Sheeva, Israel

Citation: Neulander EZ. The Endo GIA stapler in the paravaginal dissection during radical cystectomy. Cent European J Urol. 2018; 71: 391-393.

Article history

Submitted: Aug. 20, 2017

Accepted: Nov. 15, 2018

Published online: Nov. 19, 2018

Corresponding author

Endre Zoltan Neulander
Ben Gurion University
Soroka Umc Urology
Rager 1
84779 Beer Sheeva, Israel
phone: +97 250 626 0560
endre@bgu.ac.il

Introduction The articulated Endo GIA stapler has proven itself as an important addition to the technical armamentarium of radical cystectomy (RC) [1]. RC in female patients is technically more challenging than in males, especially when improved functional results and life quality issues, such as vaginal preservation and nerve sparing, are pursued. Additionally, the use of the endo stapler reduces bleeding in female cystectomy [1].

Material and methods Using the Endo GIA stapler, we performed the lateral vaginal dissection during RC (radical cystectomy) in 7 female patients with minimal blood loss and very good functional results. We were able to prevent vaginal tethering and preserve enough vaginal tissue for reconstruction over a 10 or 20 cc syringe.

Conclusions The articulated Endo GIA is a versatile and safe tool used to perform the often technically demanding lateral vaginal dissection during RC in female patients.

Key Words: endo stapler ◊ female ◊ radical cystectomy

The use of the articulated Endo GIA stapler for the haemostatic transection of the bladder pedicles during radical cystectomy (RC) has been previously described. Even though it is relatively expensive, it represents an important step forward in the surgical armamentarium since it considerably reduces operative time and blood loss. [1, 2]. RC in the female patient is technically challenging because of the close relationship of the bladder with the internal genitalia and especially the vagina. In the last three years, we have successfully used the Endo GIA stapler in radical cystectomy and anterior exenteration in 7 female patients. In addition to the severing of the bladder pedicles we used the stapling device for the lateral vaginal dissection (para colpos) i.e. ‘skeletonization’ of the vagina from the lateral vaginal vascular connective tissue structures. This maneuver is mandatory for prevention of the tethering of the vaginal circumference. It has been described by Marshall et al. and Studer et al. performed in the classical way of lateral vaginal suture ligature technique [3, 4]. As it is well known, the para colpos is abundant

in blood vessels, especially veins, that may cause severe bleeding if tempered with improperly during dissection at the time of the anterior exenteration. Also, if the paravaginal dissection is not performed correctly, the classical suture ligatures may tether the remnant vaginal walls making a functional reconstruction of the vagina very difficult if not impossible.

Surgical technical point

The major steps of cystectomy in female patients have been described elsewhere [3, 4, 5]. After the severing of the superior and mid-bladder pedicles, blunt dissection of the posterior vaginal wall from the recto sigma is performed. The mounted gauze pad in the vaginal fornix is very helpful for this maneuver. The structures lateral to the vagina, are dissected away from the lateral vaginal wall with a long tonsil or a ‘long nose’ right angle forceps. With this maneuver, a tunnel-like space parallel longitudinally with the vaginal wall is created. One of the jaws

of the Endo GIA stapler is inserted in this tunnel and the staples are fired (Figures 1, 2, 3). We tend to preferably use a 45 mm vascular stapler. This step is repeated along the length of the lateral vaginal wall down to the endopelvic fascia opening, on both sides of the vagina. The vagina is 'released' from its lateral attachments. If the dissection of the paravaginal tissue away from the vagina is done parallel to the anterior half of the lateral vagina walls (2 and 10 o'clock around the vagina) there is a reasonable chance that at least some part of the nerves coursing close to the vagina will be spared. After the dissection, incision of the lateral vaginal wall can be done close to the anterior aspect, gaining enough lateral and posterior vagina for a possible functional reconstruction over a 20 or 10 cc syringe. Further on, the cystectomy follows the steps described elsewhere. We caution against the use of the stapler for the division of the vaginal wall itself, since the staples are non-resorbable and they will be retained in the suture line of the vagina causing considerable irritation [2]. We incise the vaginal wall with the electrocautery and there is a reasonably little amount of bleeding from the vaginal incision line, if the dissection of the lateral vaginal connective and vascular structures was performed down to the vaginal wall.

DISCUSSION

In the era of major advances towards functional surgery and quality of life preservation, the handling of the vagina during radical cystectomy becomes

even more so important. This of course only in concordance with the oncologic principles of the procedure adjusted for each and every case in particular.

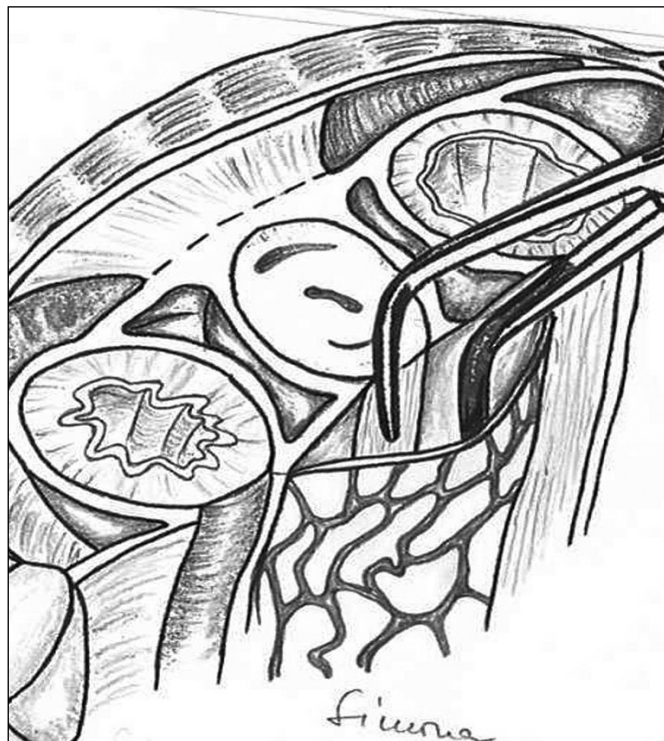
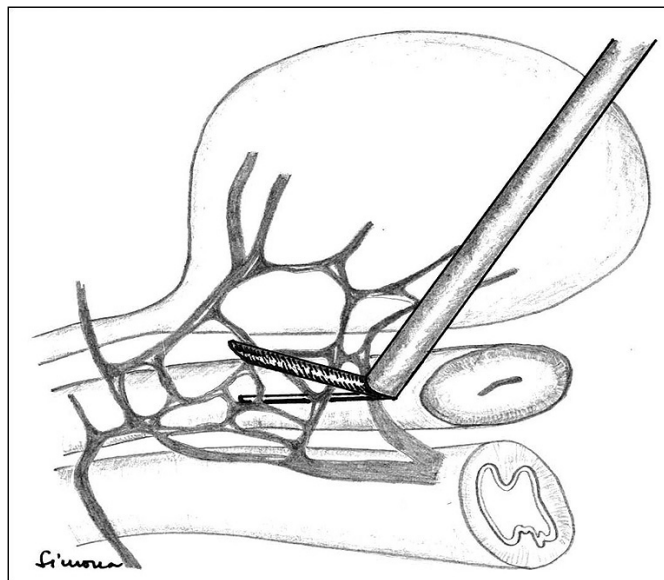
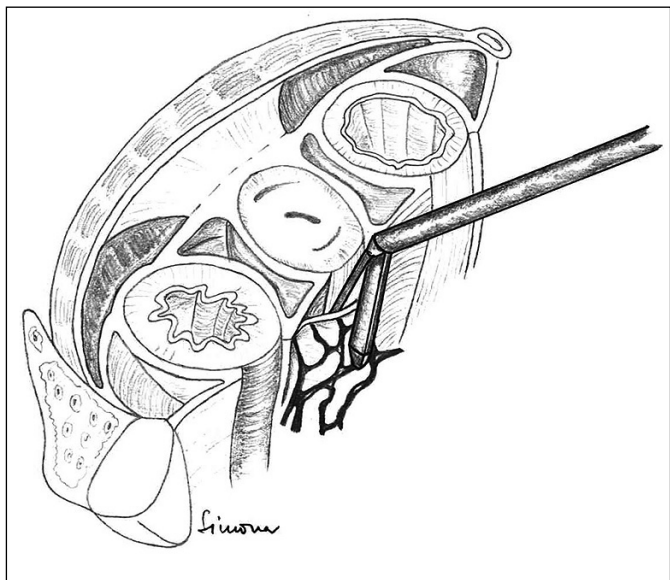


Figure 1. Represents the dissection of the paravaginal structure from the vaginal wall with a long nose right angle clamp creating a tunnel between the vagina itself and the paravaginal vascular structures.



Figures 2 and 3. After the dissection of the paravaginal vascular structures was performed with a long nose right angle clamp, in the created tunnel along the anterolateral sides of the vagina, the jaw of the Endo GIA stapler is introduced and the stapler fired severing the structures and releasing the vagina from the paravaginal tissues.

The classical technique of the radical cystectomy in female patients has been described by several formidable authors [3, 4]. Each description adds nuances and finesse to the surgical technique. We consider that the preservation of as much vaginal tissue (circumference) as possible, remains still a technical challenge especially when but not limited to the rare cases when an orthotopic neobladder is contemplated. Also in the case of an ileal conduit or continent pouch, preservation of the vaginal tissue will ensure its future functionality ensuring a better quality of life [6].

Following the lateral vaginal dissection with the Endo GIA stapler, all of our patients had the vagina reconstructed over a 10 or 20 cc syringe. The bleeding during the use of the stapler was minimal, we approximated it between 100–200 cc in comparison with 500–600 cc when using the suture ligation technique [1, 2]. None of the patients needed re-approximation of the remnant posterior vaginal wall strip (a vaginal strip laying on the anterior rectal wall) to the pubis in order to seal off the pelvis as in some of our previous cases, when not using the endo stapler, the paravaginal dissection was performed incompletely with the suture ligation technique. Consequently, we caused tethering of the remaining vaginal tissue,

which made the reconstruction of the vagina and closure of the gap between the vulva and the pelvis very difficult.

CONCLUSIONS

We used the described technique in 7 patients. We found it very versatile and reliable. The key is creating the paravaginal ‘tunnel’ with a dissection of the correct planes. We experienced a three-fold decrease in blood loss in the specific phase of the surgery, when using the Endo stapler vs. the suture ligation technique. This is not an inexpensive procedure (one 45 mm cartridge costs around 100 USD); we used at least 4 cartridges (for the vaginal dissection only). Additional cartridges are needed for the rest of the RC steps. In our opinion, the cost is compensated by the shorter operative time and diminished blood loss.

CONFLICTS OF INTEREST

The authors declare no conflicts of interest.

ACKNOWLEDGMENT

Acknowledgment to Mrs. Simona Iarca Neulander for providing the images.

References

1. Hanash KA, Peracha AM, Al-Zahrani HM, et al. Radical cystectomy: minimizing operative blood loss with a stapling technique. *Urology*. 2000; 56: 488-491.
2. Yamashita T, Muraishi O, Umeda S, Matsushita T. Radical cystectomy using endoscopic stapling devices: preliminary experience with a simple and reliable technique. *J Urol*. 1997; 157: 263-265.
3. Marshall FF, Treiger BF. Radical cystectomy (anterior exenteration) in the female patient. *Urol Clin North Am*. 1991; 18: 765-775.
4. Mills RD, Studer UE. Female orthotopic bladder substitution: A good operation in the right circumstances. *J Urol*. 2000; 163: 1501-1504.
5. Wood DP. Orthotopic urinary diversion in women. *Urol Clin North Am*. 2000; 27: 367-378.
6. Chang SS, Cole E, Cookson MS, Peterson M, Smith JA Jr. Preservation of the anterior vaginal wall during female radical cystectomy with orthotopic urinary diversion: technique and results. *J Urol*. 2002; 168: 1442-1445. ■