

Subcutaneous pyelovesical bypass – Detour bypass – as a solution for ureteric obstruction

Andrzej Jerzy Wrona, Jarosław Zgajewski, Norbert Kopeć, Dominik Chodor, Paweł Kopcza, Stefan Klekot

Biernacki Hospital Mielec, Department of Urology, Mielec, Poland

Citation: Wrona AJ, Zgajewski J, Kopeć N, Chodor D, Kopcza P, Klekot S. Subcutaneous pyelovesical bypass – Detour bypass – as a solution for ureteric obstruction. Cent European J Urol. 2017; 70: 429-433.

Article history

Submitted: April 26, 2017
Accepted: Oct. 11, 2017
Published online: Oct. 17, 2017

Corresponding author

Andrzej Jerzy Wrona
Biernacki Hospital Mielec
Department of Urology
22, Żeromskiego Street
39-300 Mielec, Poland
phone: +48 401 778 00 373
andrzejjerzywrona@gmail.com

Introduction Many patients suffer from unilateral or bilateral hydronephroses caused by pelvic tumors, retroperitoneal fibrosis, occlusion due to radiation therapy or iatrogenic damage to the ureter. Currently, percutaneous nephrostomy or double J stents are primarily used. Nephrostomy deteriorates a patient's quality of life and leads to frequent infections, blockage of tubes, or bleeding, while uretral stents are associated with septicemia and irritative bladder symptoms. Thus, a useful solution is a Detour stent.

Material and methods A Detour stent consists of an outer layer made of polytetrafluoroethylene and an inner layer that is a silicone tube 17 F wide, with perforations on both ends and a radio-opaque ring on the proximal end. The ring allows for the insertion of the Detour to the kidney in the correct way. The Detour is placed subcutaneously to the kidney and to the bladder. The route is then tunneled by the large plastic hollow tube for inserting the Detour, and its distal end is sutured to the bladder.

Results Twelve patients were operated using this method, one of which received a Detour stent bilaterally. The mean follow-up was 10 months. All patients were operated previously by different methods. The average time of surgery was 78 minutes. The following complications occurred: urinary tract infections, haematoma, obstructed flow of urine through the Detour stent, prolonged urinary leakage, and pyelonephritis.

Conclusions Subcutaneous nephrovesical bypass – Detour System – is a minimally invasive, safe and effective procedure that improves quality of life with no serious complications. The Detour System allows urine to be drained in those cases where many other treatments had failed or were not feasible.

Key Words: pyelovesical bypass ◊ retroperitoneal fibrosis ◊ ureteral obstruction ◊ quality of life ◊ ureter

INTRODUCTION

Ureteral obstruction is a severe complication of modern surgery, especially for gynecologic, colorectal and vascular pelvic surgery [1]. It can also occur after radiotherapy in the area of the abdomen and pelvis, as a result of retroperitoneal fibrosis (Ormond's disease) or squeezing of the ureter by a tumour. Due to the obstruction, patients may develop uni- or bilateral hydronephrosis. Until now, endoscopic surgery, open reconstructive surgery, temporary Double J stents or a permanent nephrostomy were the only available methods of therapy. A nephrostomy deteriorates a patient's quality of life and leads to frequent

infections, blockage of tubes or bleeding. Concurrently, ureteral stenting may be associated with sepsis, irritative bladder symptoms and a high failure rate, which ultimately leads to a nephrostomy tube [2]. As presented, such procedures, excluding nephrostomy, are technically demanding and not always successful, and may expose the patient to many complications. Most important, however, they are always temporary solutions.

Using subcutaneous pyelovesical bypasses (Detour bypass) is safe, effective and a quality-of-life improving method for channeling urine from the kidney to the bladder without the participation of the impaired ureter.

MATERIAL AND METHODS

A Detour bypass consists of two co-axial tubes: a porous 27F polytetrafluoro-ethylene (PTFE) outer tube and an inner 17F silicone tube extending beyond the PTFE at either end. There is a radio-opaque ring that marks the proximal junction between the inner silicone and outer PTFE layer, to aid in the accurate placement of the proximal end of the stent.

The procedure was performed under general anaesthesia with the patient placed in the prone position. The previously existing nephrostomy tract was used for placing the proximal end of the stent in two cases and a new tract was created under ultrasound (Figure 1) and fluoroscopic guidance in the other eleven cases. The tract was then dilated serially with metal dilators to a diameter of 30F and an Amplatz sheath was introduced under fluoroscopic control. The Detour tube was then introduced into the Amplatz sheath and the position of the radiopaque ring at the junction of the calyx and renal parenchyma was visualised by fluoroscopy. The Amplatz sheath was then removed. Next, the patient position was changed to the supine position. A horizontal suprapubic incision was made to access the bladder. The tunneling device was used to create the subcutaneous pathway from the suprapubic region to the loin. The distal end of the Detour bypass was then passed through the tunneling device to the suprapubic incision and the tunneling device was removed maintaining the bypass in place. The Detour bypass was cut for the right length for the patient and the external PTFE sheath was removed leaving a bare internal silicon tube. The distal end of the inner silicon tube was trimmed into a bevel, fenestrated, and then introduced into the dome of the bladder via a small incision. The outer PTFE layer was fixed to the bladder wall using absorbable sutures. The indwelling Foley catheter was left in situ for an average of 9 days (range: 7–13) and then removed.

RESULTS

Between October 2013 and November 2016, twelve patients (eight women and four men) with complicated ureteral obstruction received thirteen subcutaneous ureteral bypasses using the Detour bypass method. One patient had a bilateral stent implanted and eleven received a unilateral stent. The mean age of patients was 50 yr (range: 34–64). The mean follow-up was 10 mo (range: 1–39). Four patients had a history of a malignant cause of obstruction, six of non-malignant and two of idiopathic causes of ureteral obstruction. Patients were previously treated with endoscopic surgeries, open reconstruc-

tive surgeries, temporary Double J stents or permanent nephrostomy tubes.

The mean length of surgery was 78 min (range: 45–135), and the mean length of hospital stay was 14 days (range: 8–30). No intraoperative or immediate postoperative deaths were observed. Early complications were observed in 6 patients. Patient #4 developed a urinary tract infection (*Escherichia coli* and *Enterococcus faecalis*) with bacteraemia (*Escherichia coli*), a wound infection (*Enterobacter cloacae*), a hematoma at the site of nephrostomy and obstructed urine drainage through the Detour due to kinking of its renal end. The infection was manifested by fever. Due to the obstruction, the patient required a percutaneous nephrostomy. The infections were managed by intravenous antibiotics. The patient was discharge home with a percutane-

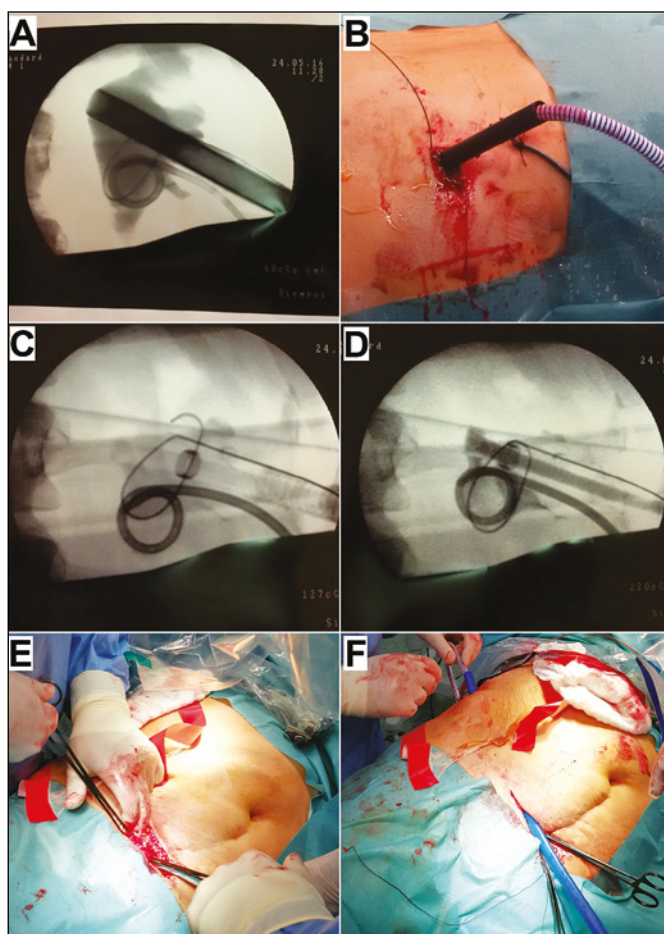


Figure 1. Steps of the procedure. A. Positioning of the Amplatz sheath under a fluoroscopy. B. Introducing Detour stent into the Amplatz sheath. C. Positioning of the radiopaque ring at the junction of the calyx and renal parenchyma. D. Contrast agent seen in the Detour stent. E. Accessing the bladder via a suprapubic incision. F. Creating the subcutaneous pathway from the suprapubic region to the loin using a tunneling device.

Table 1. Summary of all cases treated with the Detour stent

	Sex	Side	Age	Follow-up (months)	Etiology	Previous treatment	Time of surgery (minutes)	LOS (days)	Early complications	Late complication
Case #1	F	Right	43	39	Cervical cancer, Radiotherapy	Open reconstructive surgery Nephrostomy 'U'	105	19	Blood transfusion	Irritative symptoms right bypass encrustation and obstruction requiring PCN
		Left	45	7	Cervical cancer, Radiotherapy	Open reconstructive surgery Double J stent	120	19	Prolonged urine leakage	Irritative symptoms
Case #2	M	Right	64	22	Retroperitoneal fibrosis	Nephrostomy	105	11	None	–
Case #3	F	Right	62	13	Retroperitoneal fibrosis	Nephrostomy	90	12	None	Irritative symptoms
Case #4	F	Right	49	13	UPJ obstruction	Endopielotomy Open reconstructive surgery Nephrostomy	60	30	Sepsis wound infection subcutaneous hematoma bypass kinking	Recurrent urinary tract infections bypass encrustation, obstruction requiring PCN
Case #5	M	Left	48	9	Retroperitoneal fibrosis	Double J stent Nephrostomy	135	11	None	Recurrent urinary tract infection
Case #6	F	Right	34	7	Idiopathic obstruction of distal ureter	Two open reconstructive surgeries Nephrostomy	95	12	Blood transfusion	Recurrent urinary tract infection irritative symptoms
Case #7	F	Left	63	7	Jatrogenic injury during surgery of retroperitoneal sarcoma	Nephrostomy	50	11	None	Bypass encrustation and obstruction requiring PCN
Case #8	F	Right	36	7	Cervical cancer Radiotherapy	Open reconstructive surgery Nephrostomy	100	12	None	Recurrent urinary tract infections
Case #9	M	Left	47	4	Unknown/ Idiopathic obstruction of distal ureter	Two open reconstructive surgeries Double J stent Nephrostomy	50	11	None	Recurrent urinary tract infections
Case #10	F	Left	64	1	Cervical cancer Radiotherapy	Double J stent Nephrostomy	70	8	Blood transfusion	–
Case #11	F	Right	48	1	Jatrogenic injury	Double J stent	65	7	None	–
Case #12	M	Left	59	1	Jatrogenic injury	Double J stent Nephrostomy	45	25	Pyelonephritis subcutaneous haematoma	–
Case #13	F	Left	77	1	Cervical cancer, Radiotherapy	Double J stent Nephrostomy	60	8	None	–

ous nephrostomy placed in situ. One month later when urine and blood cultures were sterile, the patient underwent a percutaneous nephroscopy. During this procedure, kinking of the silicone inner tube of the Detour was repaired by placing the tube in the correct position. The correct urine drainage by the Detour stent was visualized in pyelography. A urine culture was sterile. Three patients needed blood transfusions after the procedure due to excessive blood loss. Patient #1 had prolonged urinary leakage after the second procedure (left side) through the suprapubic incision. It was managed by prolonged bladder catheterisation. Patient #12 developed a haematoma at the site of the nephros-

tomy and pyelonephritis (*Enterococcus faecalis*) with fever and signs of septic shock. The pyelonephritis was managed by intravenous antibiotics and the haematoma was drained surgically.

Three patients were followed up too shortly (1 month) to make conclusions about long term outcome. During follow-up, five patients complained of recurrent urinary tract infections. Four patients felt urgency and this was managed by a beta-3-adrenergic agonist. Three patients developed stent encrustation and urine drainage obstruction. Patient #4 was hospitalized 12 months after Detour bypass placement due to pyelonephritis with fever and obstructed urine drainage through the bypass. The patient required

a percutaneous nephrostomy and intravenous antibiotics. During the patient's hospitalization, a percutaneous nephroscopy and a retrograde endoscopy of the Detour bypass using a semirigid ureterscope were performed. The encrustation of both renal and vesical ends of the stent was observed, and the lumen of the bypass was transformed into a C shape and was completely obstructed by stones. Two Double J stents were passed through the stent. The patient was discharge home with Double J stents in situ, and the nephrostomy was removed. Patient #1 had obstruction of the right sided stent (39 mo follow-up) due to encrustation. The patient was hospitalized, and a percutaneous nephrostomy was placed. The obstruction was treated endoscopically in the same way as in patient #4. The patient was discharged home without a nephrostomy. Patient #8 also required a percutaneous nephrostomy due to encrustation and at the time of writing this article, the patient was waiting for hospitalization. None of the patients felt discomfort with the stent under the skin. Renal function did not deteriorate significantly in any patient.

DISCUSSION

Ureteral obstruction, caused by either benign or malignant disease, may be managed by a few different methods. The highly invasive procedures (e.g. ureterocystoneostomy, ureterocutaneostomy, ileal conduit) are available for selected patients. The least invasive treatment of ureteral obstruction is implantation of a ureteral Double J catheter. However, urinary drainage through the Double J catheter may be insufficient in some patients due to an external obstruction of the ureter or blockage of the stent lumen by mucus or necrotic material [3, 4].

When ureteral stent implantation is insufficient or impossible due to complete ureteral obstruction, and highly-invasive surgical procedures are inapplicable, permanent nephrostomy remains the traditional solution. Although its placement is safe and quick, the patients' tolerance is low. Percutaneous nephrostomy reduces quality of life as many patients withdraw themselves from social activities. There is a high rate of tube dislodgement, encrustation, infection and occlusion; therefore, the timespan between exchanges may be very short [2, 3].

The introduction of a subcutaneous pyelovesical bypass allows patients to be free of external drainage devices and improves their quality of life [5]. It may be offered as an alternative to nephrostomy for patients suffering from either benign or malignant diseases.

The Detour bypass is a closed system, so in comparison to a nephrostomy, the risk of infection is limited but it does exist – as presented in this study. It pre-

vents regular rehospitalization due to exchanging of Double J stents or managing dislocated, blocked or infected nephrostomies. There are certain advantages resulting from the unique construction of the Detour bypass. The tube is designed to be self-sustained and the inner silicone part minimizes contact between the outer PTFE coat and urine, therefore reducing risk of encrustation. Even if this complication occurs, it can be managed using a flexible ureterscope [3, 6], because of the large lumen of the tube. Subcutaneous pyelovesical bypass has been also used in select patients with ureteral stricture after renal transplantation with no native ureter available for reconstruction [7, 8, 9]. Long term follow-up confirmed the safety and efficiency of this solution. Although the use of prosthetic devices is not recommended in patients taking immunosuppressive medications, Muller et al. [7] showed acceptable rate of infection with no mechanical complications associated with Detour.

Due to the experimental nature of the Detour implantation procedure, minimal experience of the center and scarce literature available, the initial length of stay and the time of surgery was prolonged, allowing the authors to observe patients closely and by that, acquire more experience. As a result, the length of stay was shortened, except in patients with severe complications (e.g. sepsis, pyelonephritis, haematoma) who required prolonged hospitalization. Those patients who required a blood transfusion prior to the procedure suffered from mild anaemia and the blood loss during the operation worsened blood cell counts, hence indicating blood transfusions.

Four patients stayed in follow-up for more than a year, during which the Detour tube remained fully functioning, although in two cases, bypass encrustation occurred. This complication, also described by other authors [3, 6], was managed using a ureterscope. There was no recurrence of encrustation.

CONCLUSIONS

Subcutaneous pyelovesical bypass (Detour system) is a safe, minimally invasive and highly effective alternative for permanent percutaneous nephrostomy or ureteral stent in patients with ureteral obstruction caused by both malignant or benign diseases. Potential complications – e.g. infection, encrustation – may be easily and efficiently managed. Further studies on larger group of patients, assessing long-term complications and measuring exact quality of life, should be performed.

CONFLICTS OF INTEREST

The authors declare no conflicts of interest.

References

1. Burks FN, Santucci RA. Management of iatrogenic ureteral injury. *Ther Adv Urol* 2014; 6: 115-124.
2. Ahmad I, Saeed Pansota M, Tariq M, Shahzad Saleem M, Ali Tabassum S, Hussain A. Comparison between double J (DJ) Ureteral stenting and percutaneous nephrostomy (PCN) in obstructive uropathy. *Pak J Med Sci*. 2013; 29: 725-729.
3. Jurczok A, Loertzer H, Wagner S, Fornara P. Subcutaneous nephrovesical and nephrocutaneous bypass: palliative approach to ureteral obstruction caused by pelvic malignancy. *Gynecol Obstet Invest*. 2005; 59: 144-148.
4. Desgrandchamps F, Cussenot O, Meria P, Cortesse A, Teillac P, Le Duc A. Subcutaneous urinary diversions for palliative treatment of pelvic malignancies. *J Urol*. 1995; 154: 367-370.
5. Lloyd SN, Tirukonda P, Biyani CS, Wah TM, Irving HC. The detour extra-anatomic stent- a permanent solution for benign and malignant ureteric obstruction? *Eur Urol*. 2007; 52: 193-198.
6. Haddad N, Andonian S, Anidjar M. Simultaneous bilateral subcutaneous pyelovesical bypass as a salvage procedure in refractory retroperitoneal fibrosis. *Can Urol Assoc J*. 2013; 7: e417-e420.
7. Muller CO, Meria P, Desgrandchamps F. Long-term outcome of subcutaneous pyelovesical bypass in extended ureteral stricture after renal transplantation. *J Endourol*. 2011; 25: 1389-1392.
8. Azhar RA, Hassanain M, Aljiffry M, et al. Successful salvage of kidney allografts threatened by ureteral stricture using pyelovesical bypass. *Am J Transplant*. 2010; 10: 1414-1419.
9. Yazdani M, Gharaati MR, Zargham M. Subcutaneous nephrovesical bypass in kidney transplanted patients. *Int J Organ Transplant Med*. 2010; 1: 121-124. ■