

Nephrobronchial fistula. A case report and review of the literature

Jonathan A. Harikrishnan, Thomas C. Hall, Simon J. Hawkyard

Department of Urology, Scarborough General Hospital, Scarborough, North Yorkshire, United Kingdom

KEY WORDS

nephrobronchial fistula ▶ pyonephrosis ▶ nephrectomy ▶ xanthogranulomatous pyelonephritis

ABSTRACT

Nephrobronchial fistulas are a rare complication of xanthogranulomatous pyelonephritis. We report the diagnosis of such a case together with its investigation, management and a review of current literature.

CASE REPORT

A 37-year-old lady presented to our department with an incidental large left sided renal calculus discovered on routine antenatal ultrasonography. This was asymptomatic and non-obstructing and therefore treated conservatively. She had a background of recurrent urinary tract infection but no other co morbidities. Shortly after the birth of her second child she was admitted acutely to our department with left loin pain and pyrexia. An ultrasound was performed and an obstructing upper tract calculus identified. This required percutaneous nephrolithotomy. She subsequently had a parathyroidectomy for a benign adenoma causing hypercalcemia.

The patient, aged 45, was admitted acutely with left sided loin pain, pyrexia, and purulent urine. Renal ultrasound, cystoscopy, ureteroscopy, and retrograde ureterogram were performed. They demonstrated a large multiloculated collection around a non-functioning left kidney. A plan

was made to perform a left nephrectomy. This was not completed, however, as dissection proved difficult secondary to intraoperative hemorrhage. Instead open abscess drainage was performed. Postoperative recovery was unremarkable and she was discharged home five days later.

After six years she was admitted on three occasions with recurrent pyrexia, rigors, and suspected urinary tract infections over the course of a month. None of these required intervention other than with antibiotics. Blood tests were unremarkable, urine cultures were sterile, and ultrasound reported as normal. An outpatient abdominopelvic CT was organized and revealed a swollen left kidney with ureteric obstruction. A left nephrostomy was inserted. *Proteus* species was cultured in the aspirated pus. She improved with antibiotic therapy.

A nephrostogram was performed and at that time the patient complained of a bitter taste in her mouth and expectorated contrast fluid. The nephrostogram revealed contrast crossing the diaphragm in accordance with a nephrobronchial fistula (Figs. 1, 2, 3).

She underwent a left nephrectomy and the fistula tract was closed, histology confirmed this was xanthogranulomatous pyelonephritis. She underwent an uncomplicated post-operative course and was discharged home.

DISCUSSION

Xanthogranulomatous pyelonephritis (XGP) is an atypical chronic inflammatory disorder of the kidney. It is characterized by a destructive mass that leads to an infectious renal phlegmon. Parsons et al. described XGP as an invasive disease that commonly fistulates with adjacent structures [1]. It is frequently associated with repeated ureteric obstruction, infection, and immunocompromise. Our patient grew a culture positive

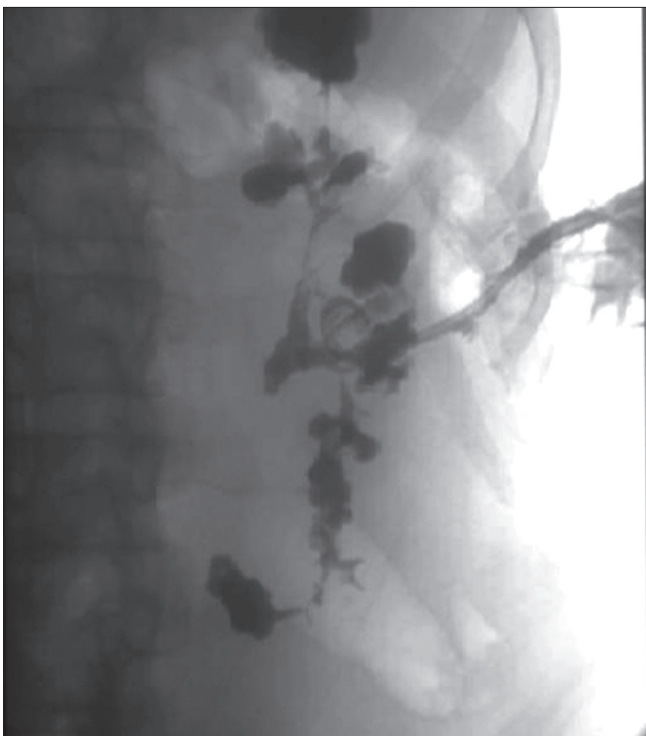

Fig. 1. Nephrostogram.

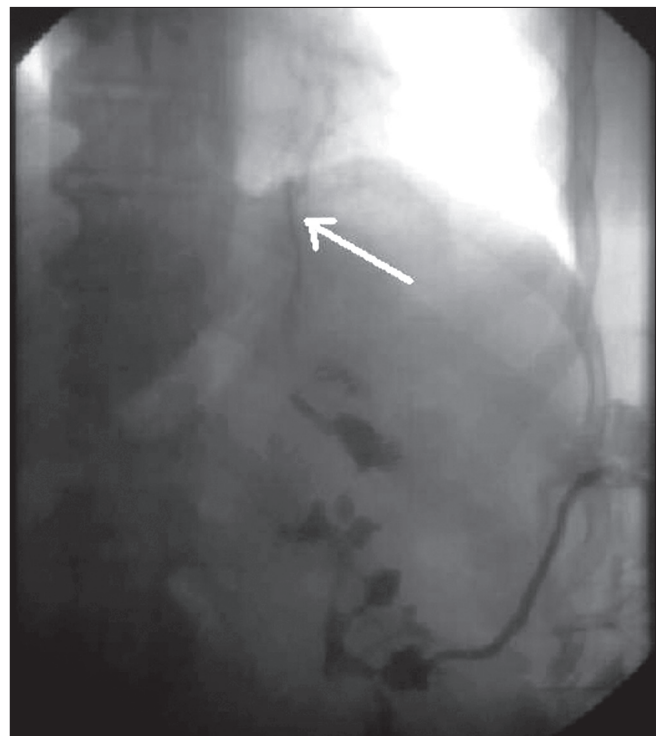


Fig. 2. Nephrostogram (fistulous tract indicated by white arrow).